

DVT



Dan Price MD
4 September 2008
Cambridge

Yes/No question

- Do the femoral & popliteal veins compress?

Why?

- DVT is bad
- History not diagnostic
- Exam unreliable
- Imaging not always available
- Heparin can be dangerous

Puzzle pieces

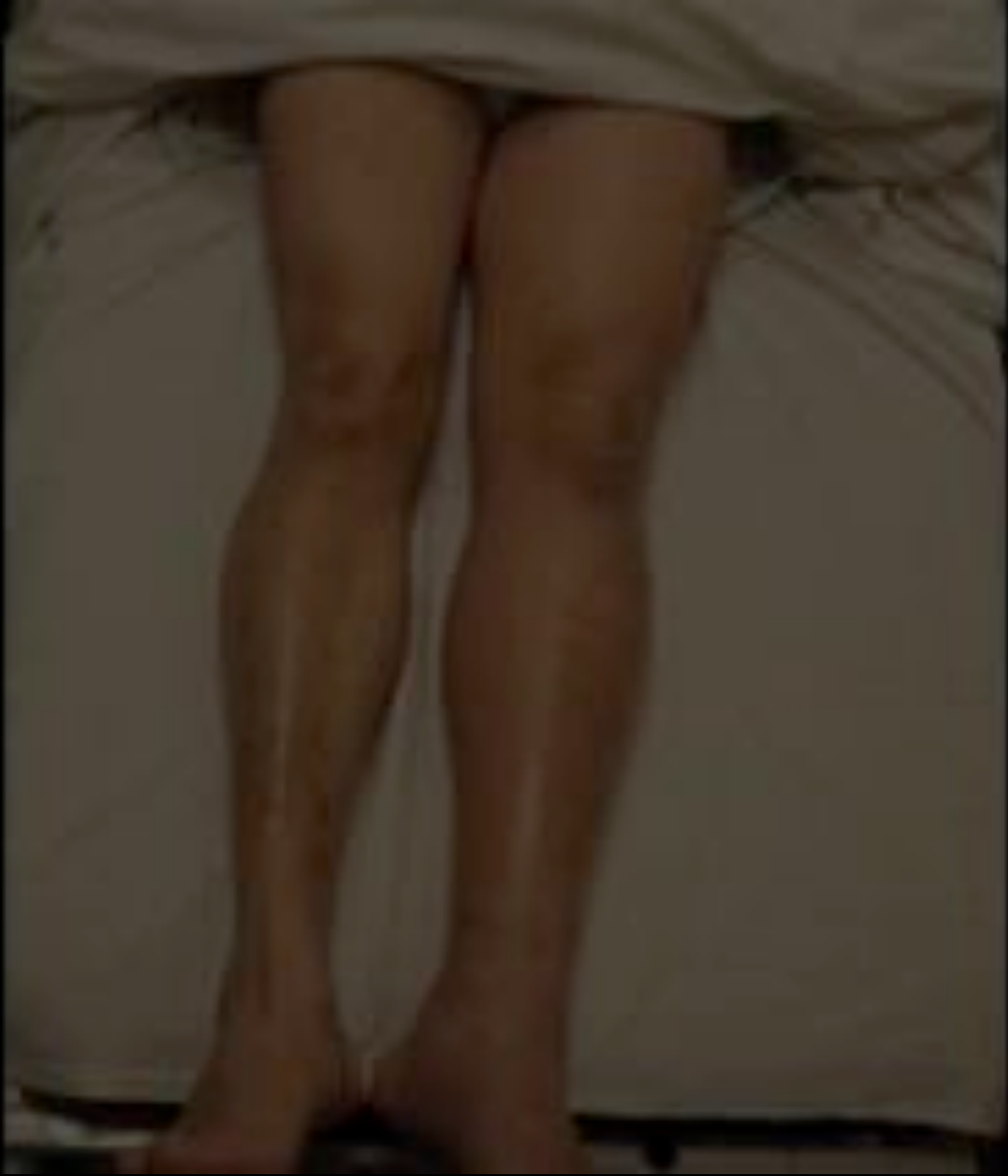- History
- Exam
- Lab
- Imaging

History

- Wells criteria
 - Active cancer
 - Leg immobilization
 - Bedridden > 3 days
 - Surgery < 4 wks

Exam

- Wells criteria
 - Localized tenderness
 - Entire leg swollen
 - Calf swelling > 3 cm
 - Pitting edema
 - Collateral superficial veins

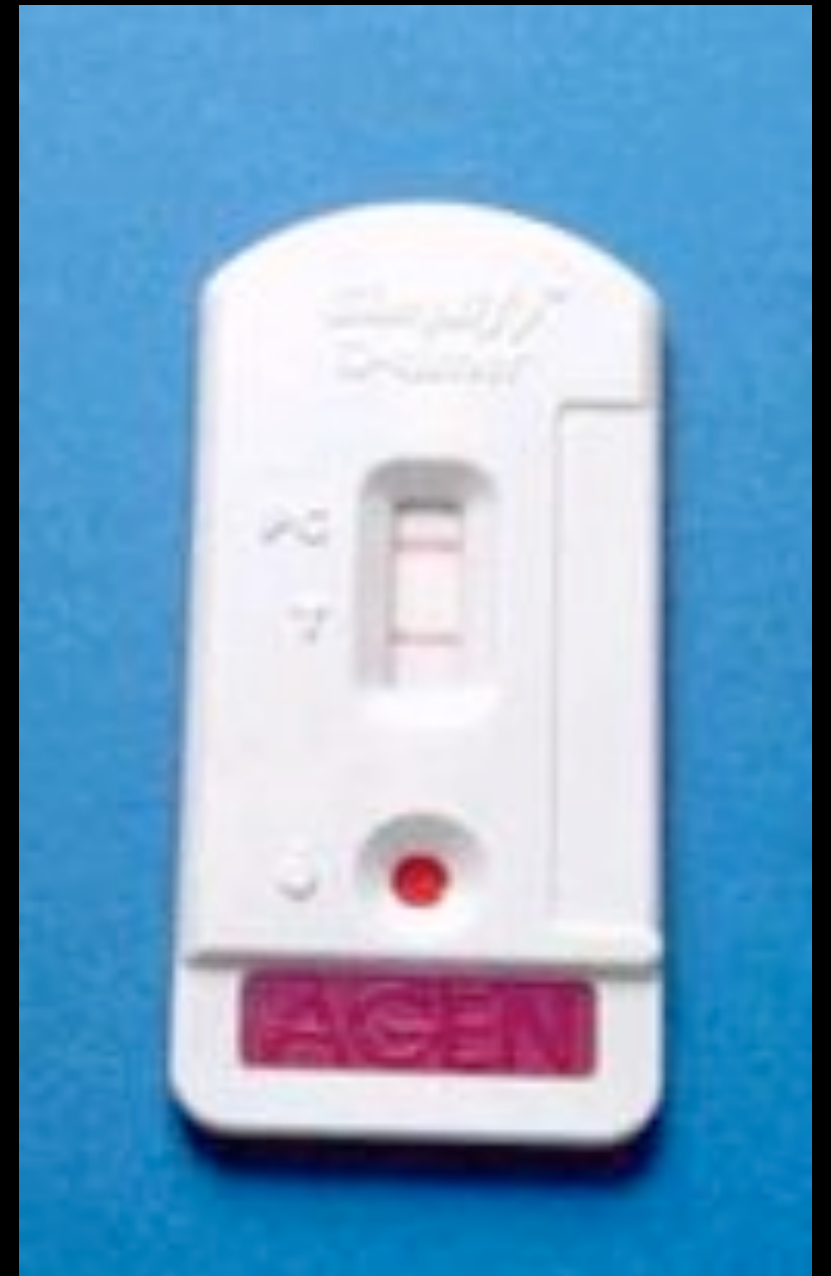

Wells criteria

- Probability
 - Low ≤ 0 points
 - Moderate 1-2 points
 - High ≥ 3 points

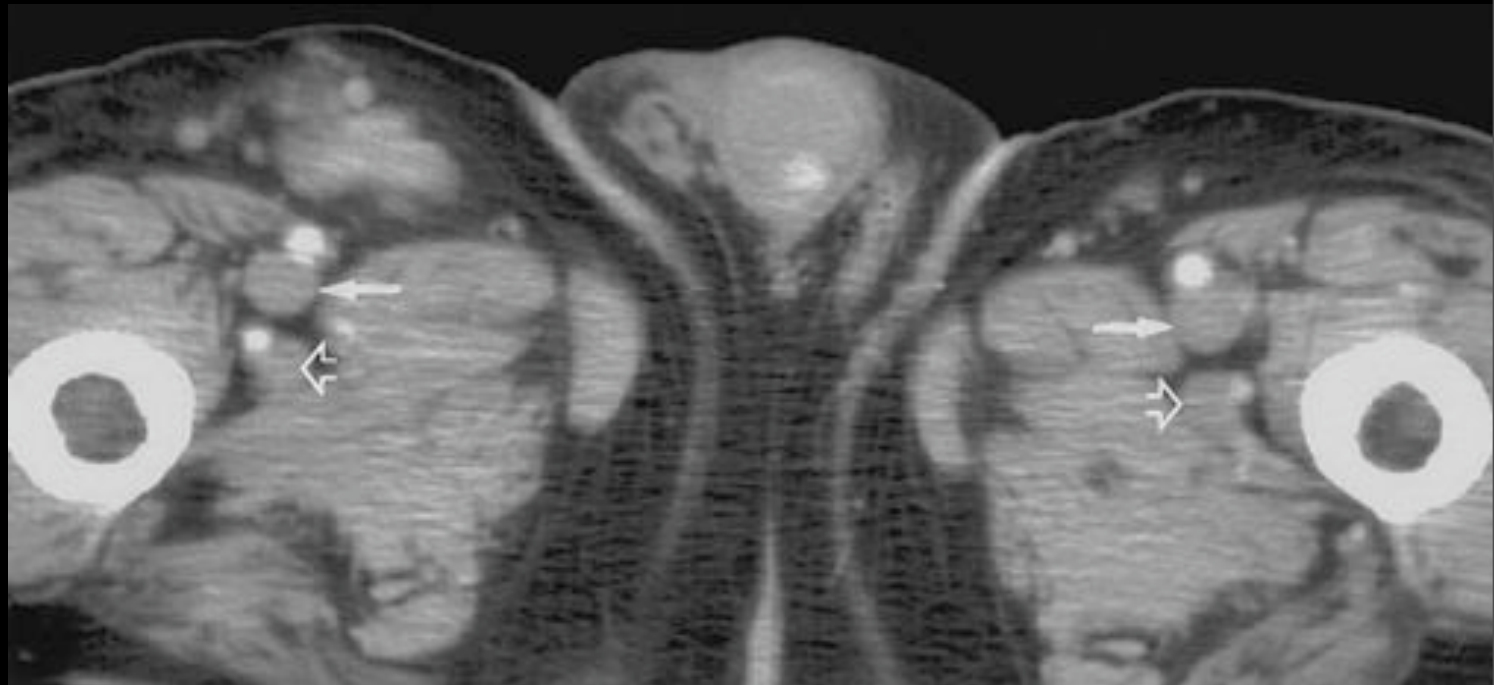
Lab

- D-dimer



Imaging

- Venography
- MRI
- CT
- Ultrasound



Management: positive

Management: positive

- Treat with LMWH

Management: normal U/S

Management: normal U/S

- Low probability with negative U/S →
DVT ruled out

Management: normal U/S

- Low probability with negative U/S → DVT ruled out
- Moderate or high probability → CT or f/u ultrasound 3-5 days

Management: normal U/S

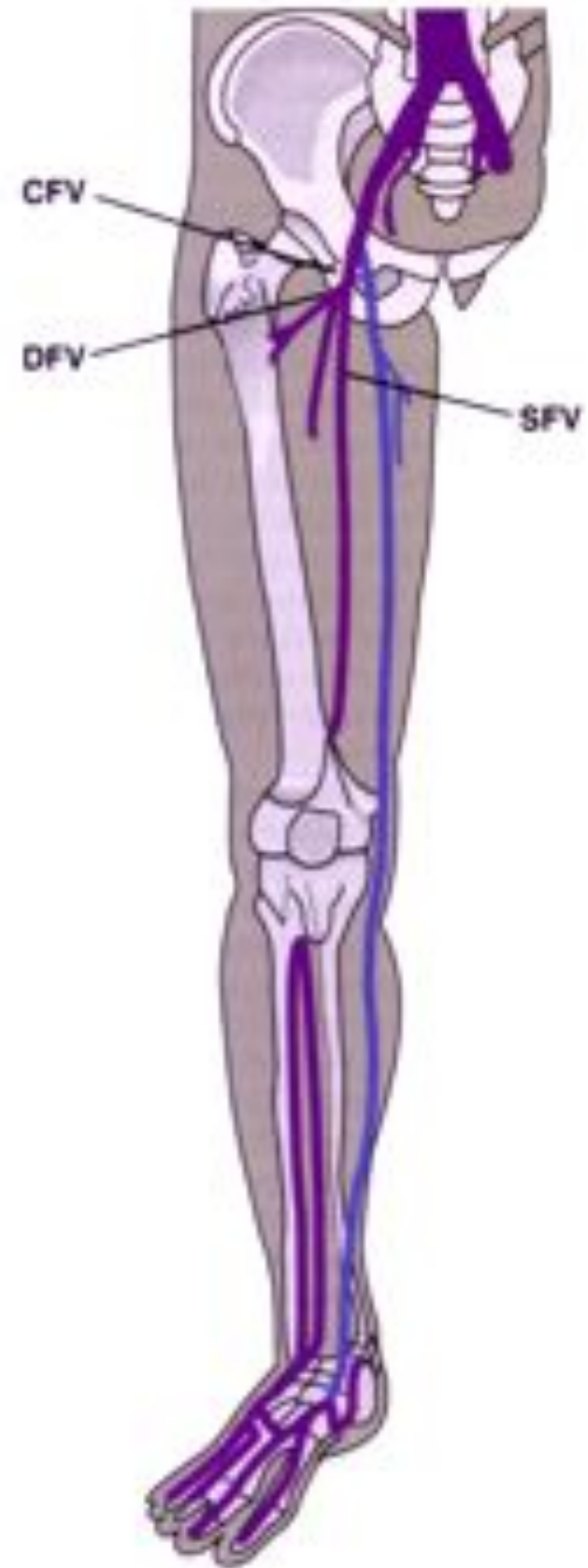
- Low probability with negative U/S → DVT ruled out
- Moderate or high probability → CT or f/u ultrasound 3-5 days
- High probability → CT

Management: indeterminent

Management: indeterminent

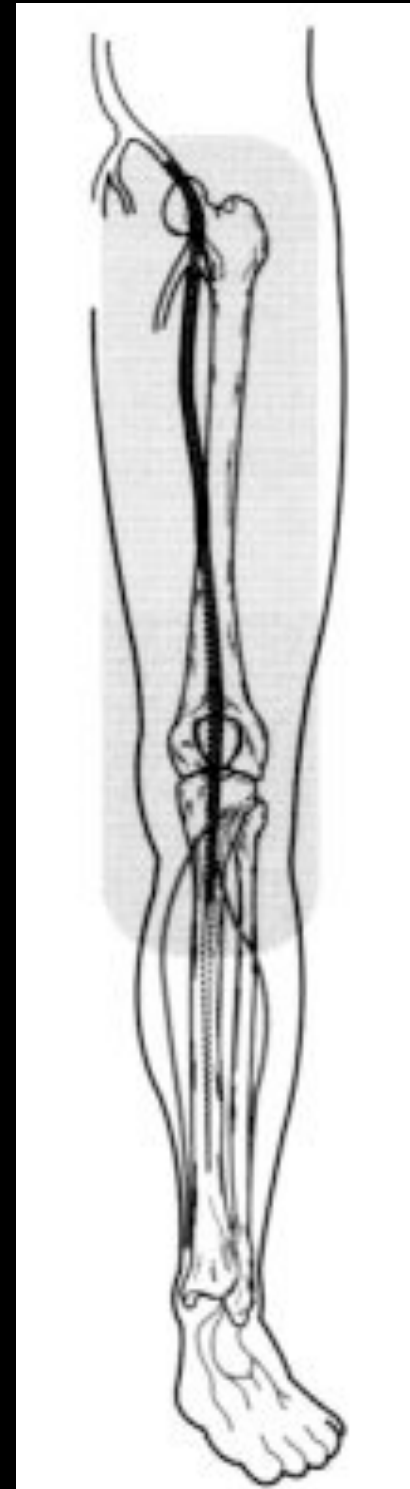
- Alternative testing (eg CT)

Anatomy



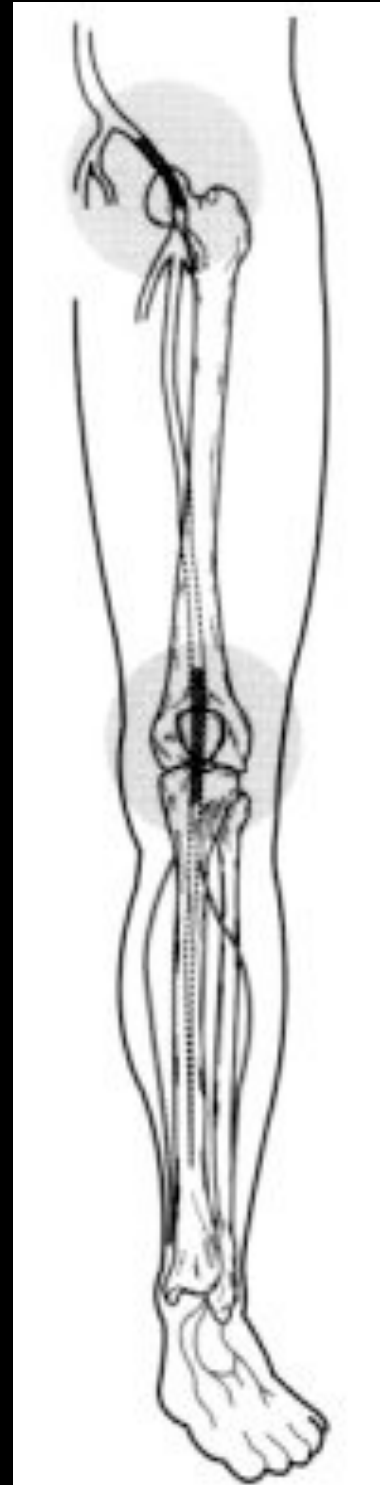
Ultrasound exam

- Duplex
 - Venous compression
 - Augmentation
 - Spontaneity
 - Phasic variation



Ultrasound exam

- Focused emergency exam
 - Compression only
 - CFV to bifurcation
 - Popliteal vein



Ultrasound exam

- Linear transducer
- 30-45° reverse Trendelenburg
- Adjust depth



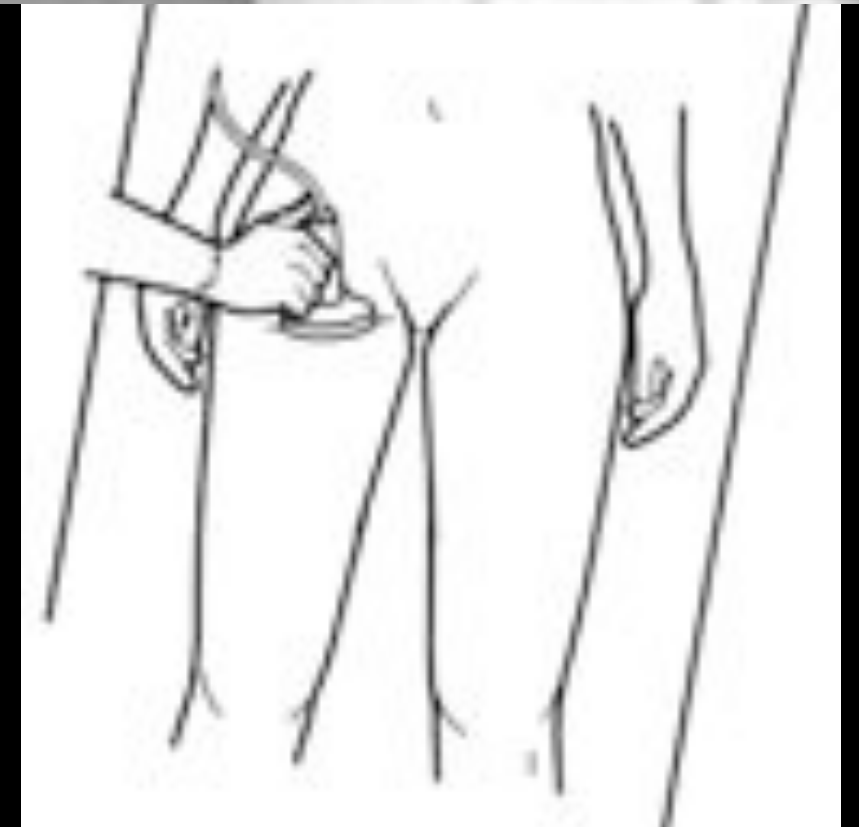Ultrasound exam

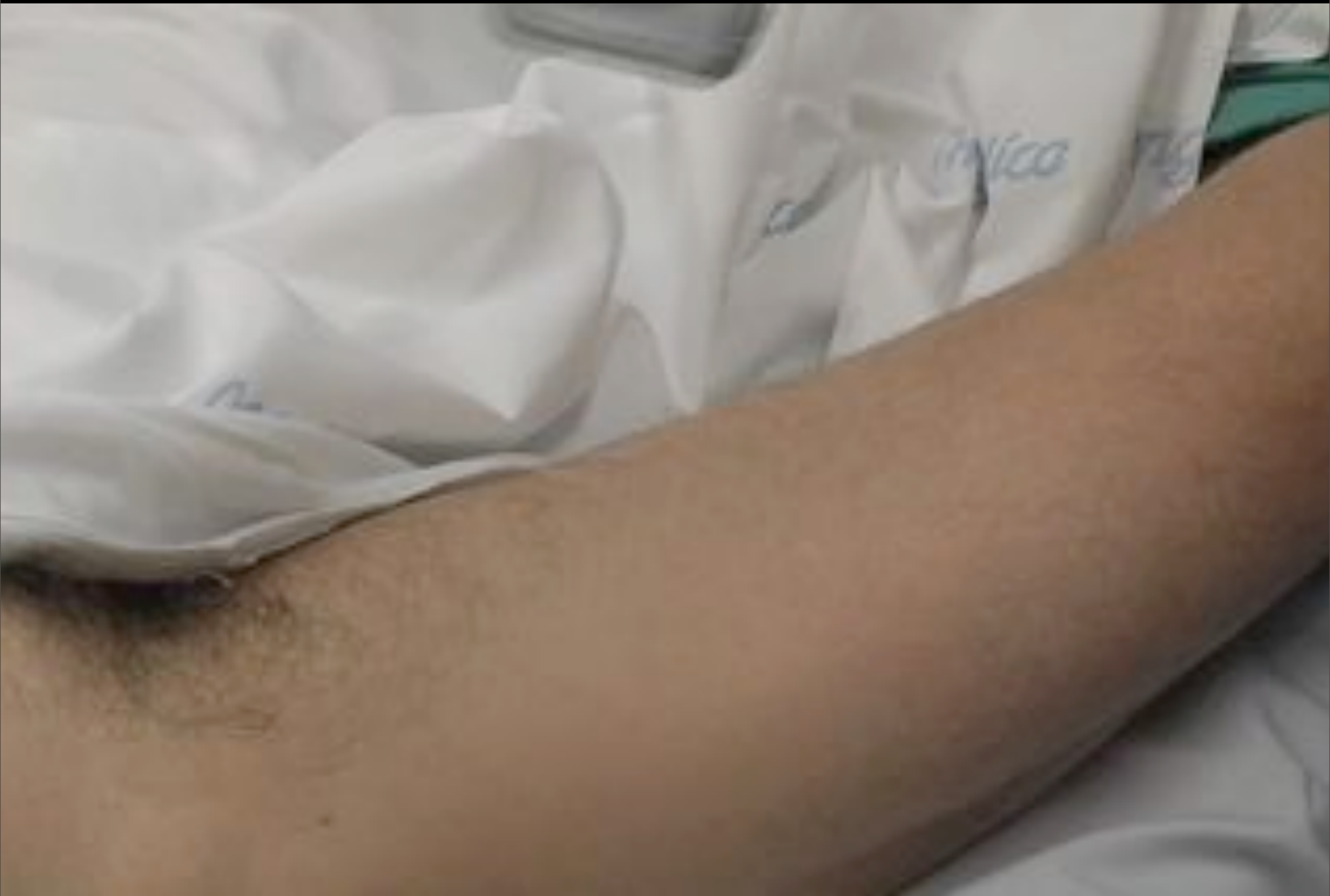- Femoral vein
 - Knee flexed
 - Hip ext rotated
 - Transverse view
 - Follow as far as possible



Ultrasound exam

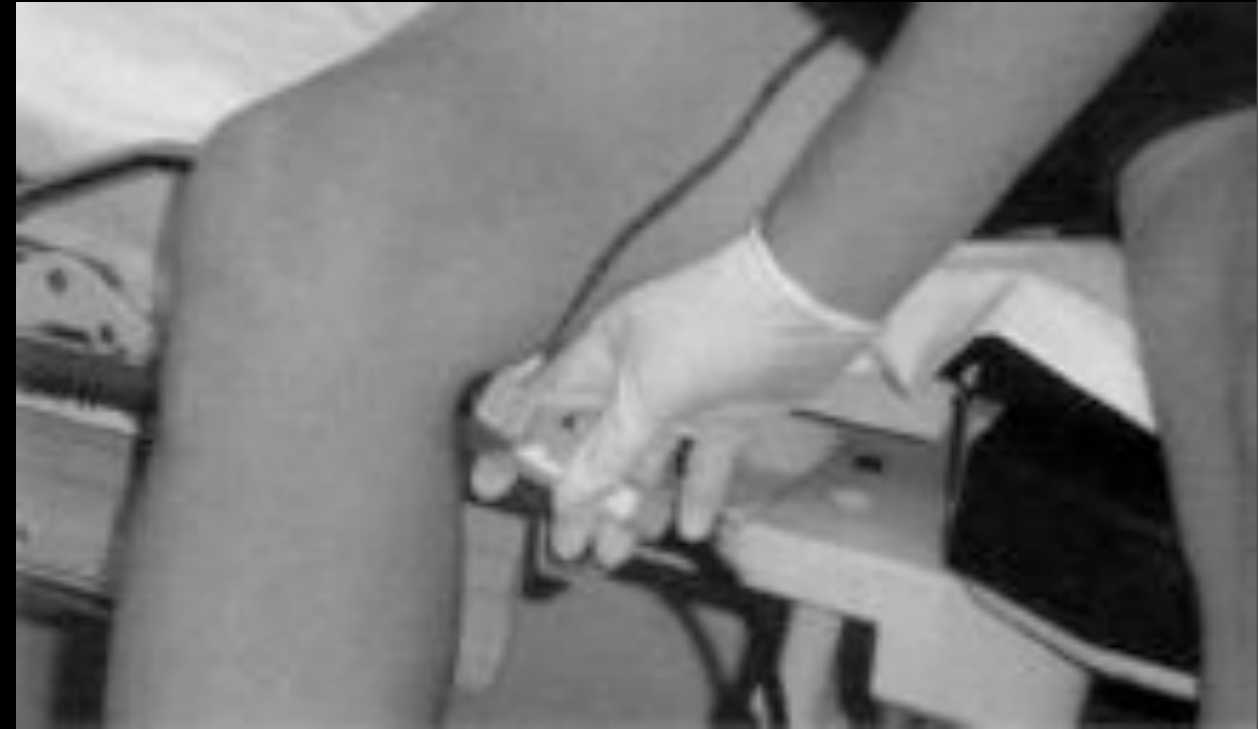- Femoral vein
 - Knee flexed
 - Hip ext rotated
 - Transverse view
 - Follow as far as possible





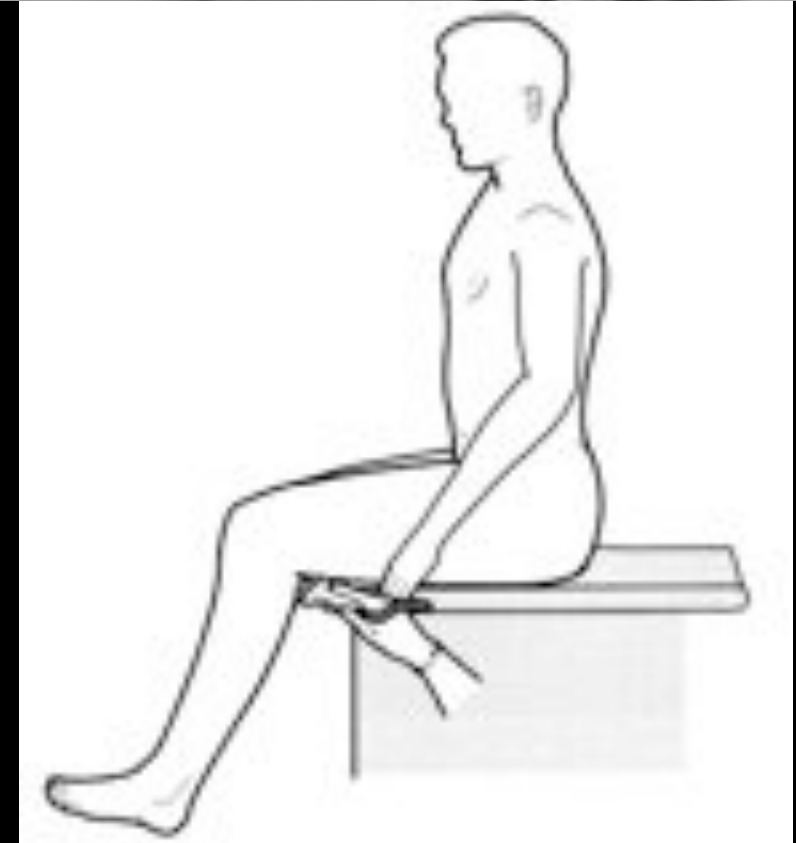Ultrasound exam

- Popliteal vein
 - Dangle legs
 - Transverse view
 - Follow through popliteal fossa



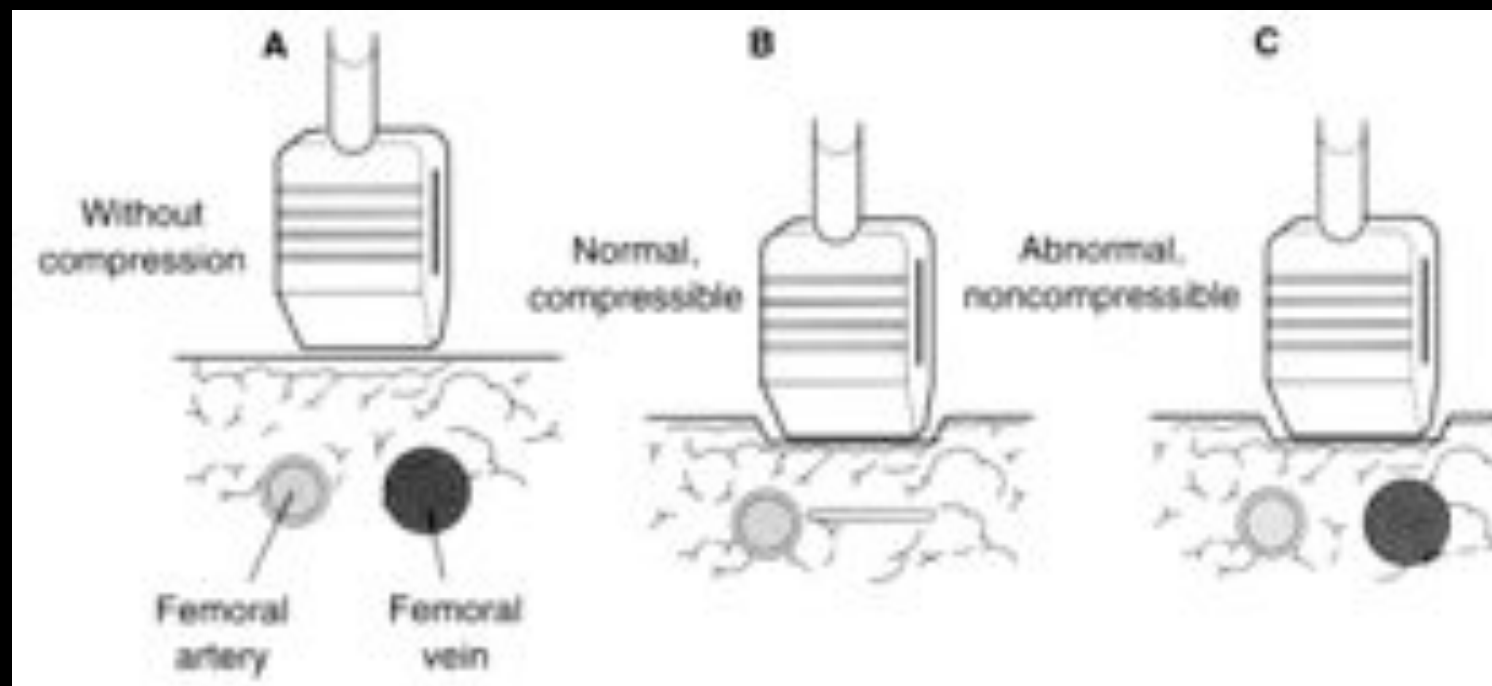
Ultrasound exam

- Popliteal vein
 - Dangle legs
 - Transverse view
 - Follow through popliteal fossa



Ultrasound exam

- Compression
 - Complete coaptation = normal
 - Deformity of artery indicates excessive pressure = DVT



Normal: Femoral

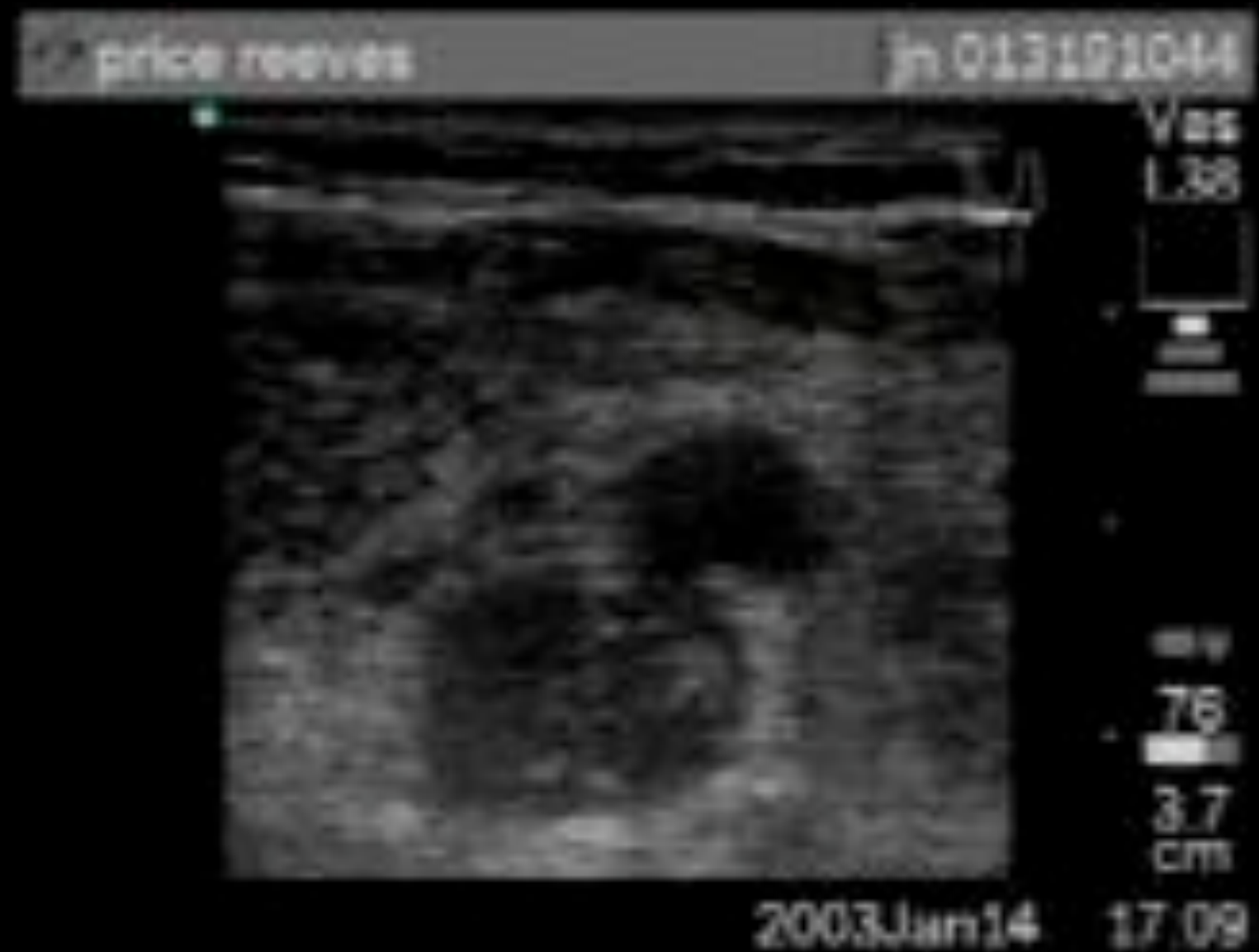NORMAL EXAM

Normal: Popliteal

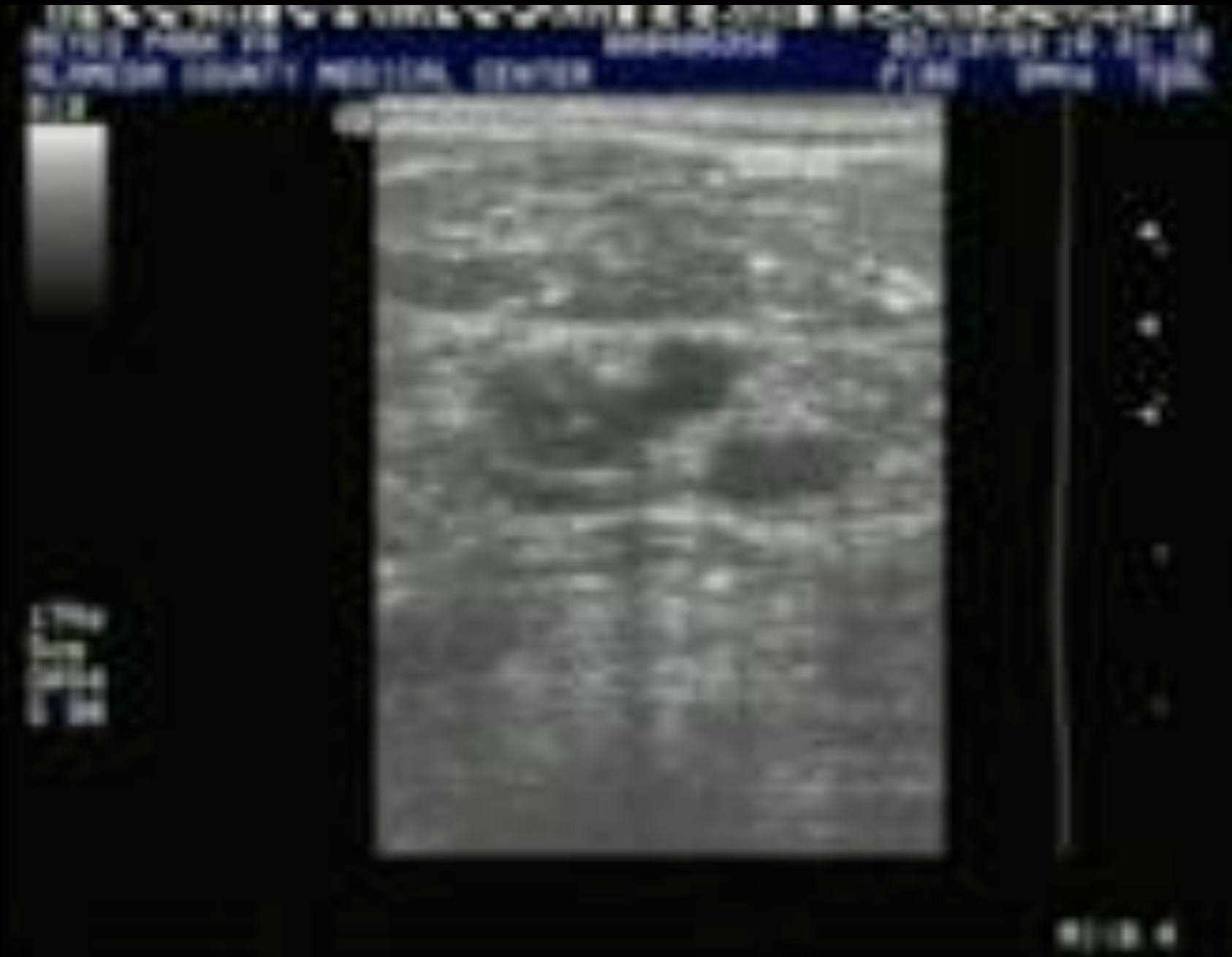Acute DVT: Femororal

Acute DVT: Femoral

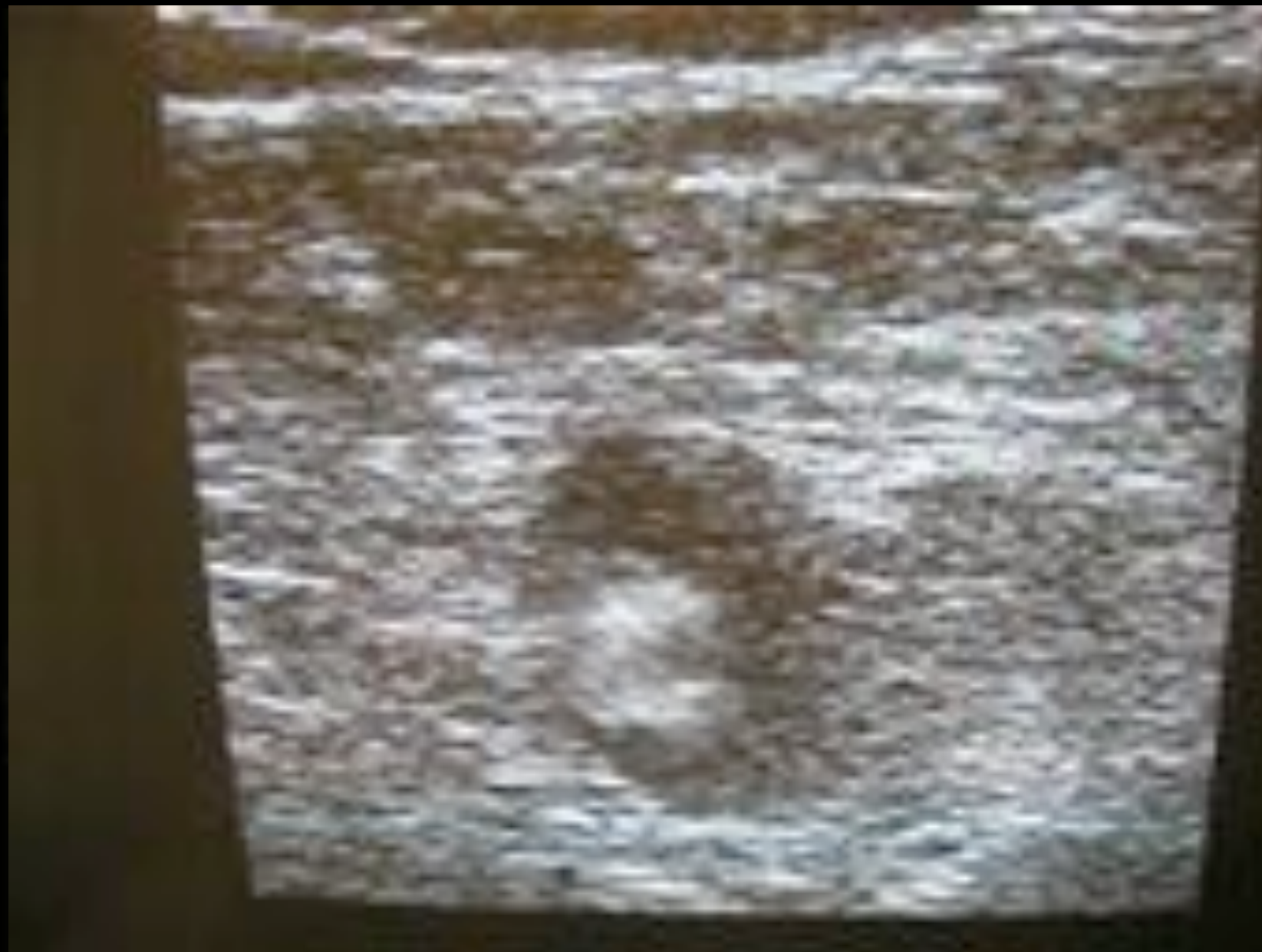
Acute DVT: Femoral



Acute DVT: Femoral



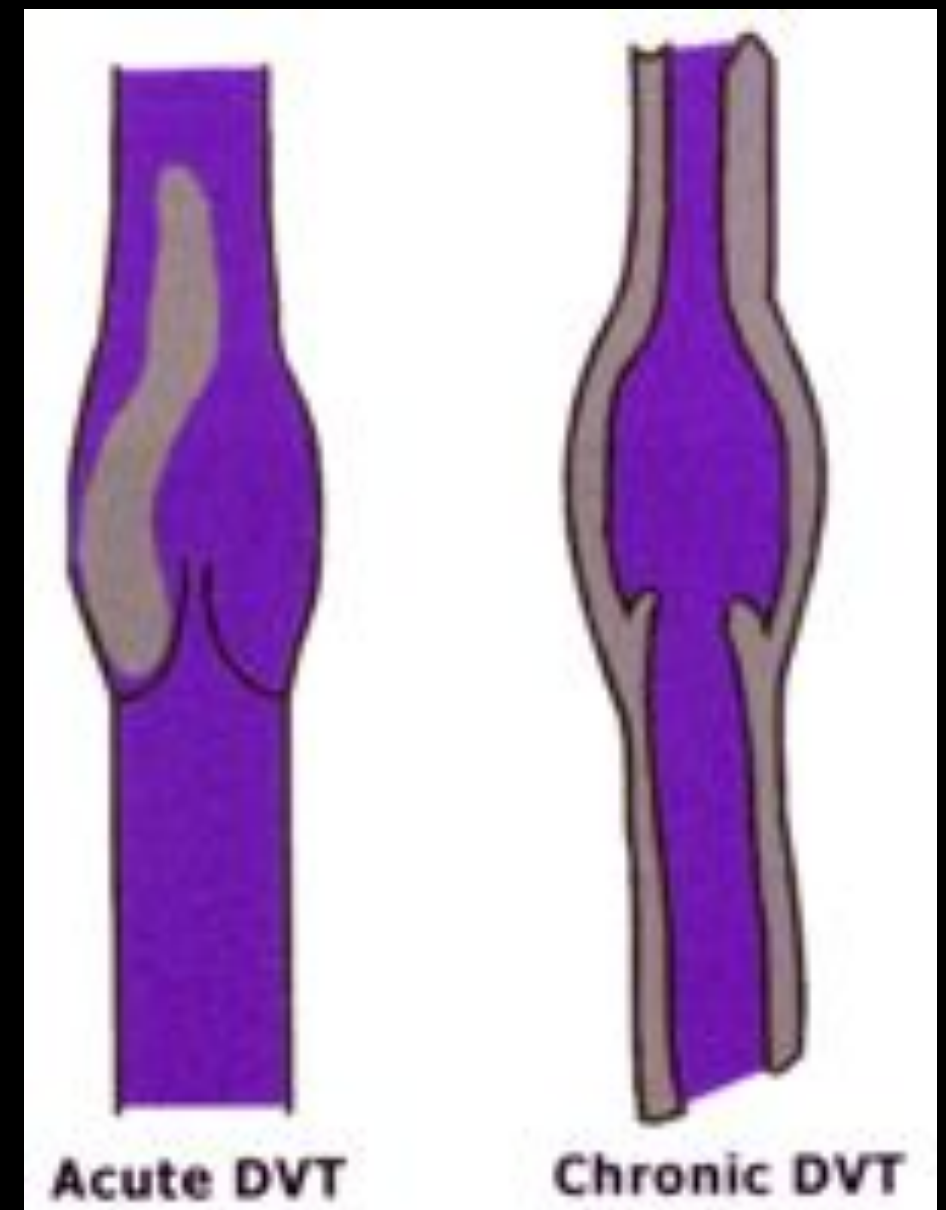
Acute DVT: Femoral



01:28:41

Chronic DVT

- Adherent to wall or walls thickened
- DVT returns to normal in 50%
- Echogenic vs lucent acute clot



Pearls & pitfalls

- Visualization of clot unreliable
- Baker's cyst
- Abdominal probe in obesity

Pearls & pitfalls

- Lymph nodes
- Finding popliteal vein
 - Light touch
 - Doppler \pm augmentation
 - Reposition pt

Review

Review

- How do we diagnose a DVT?

Review

- How do we diagnose a DVT?
- What do we do with normal exam?

Review

- How do we diagnose a DVT?
- What do we do with normal exam?
- How do we improve difficult views?

Cheers

