

Foreign bodies

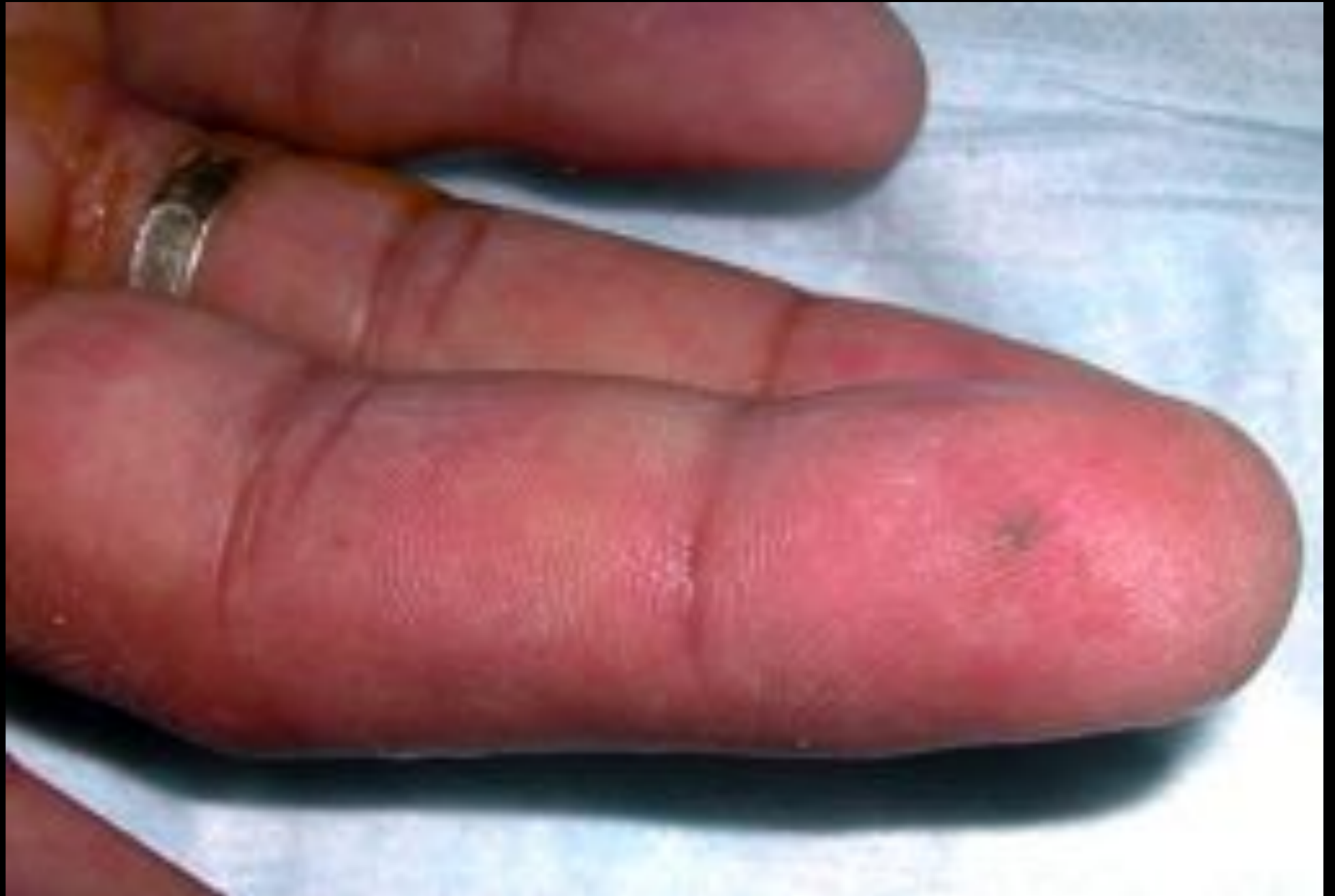Daniel Price MD

Foreign bodies

- 30 year old ♂ carpenter
 - Wood splinter
 - Nothing seen on Xray

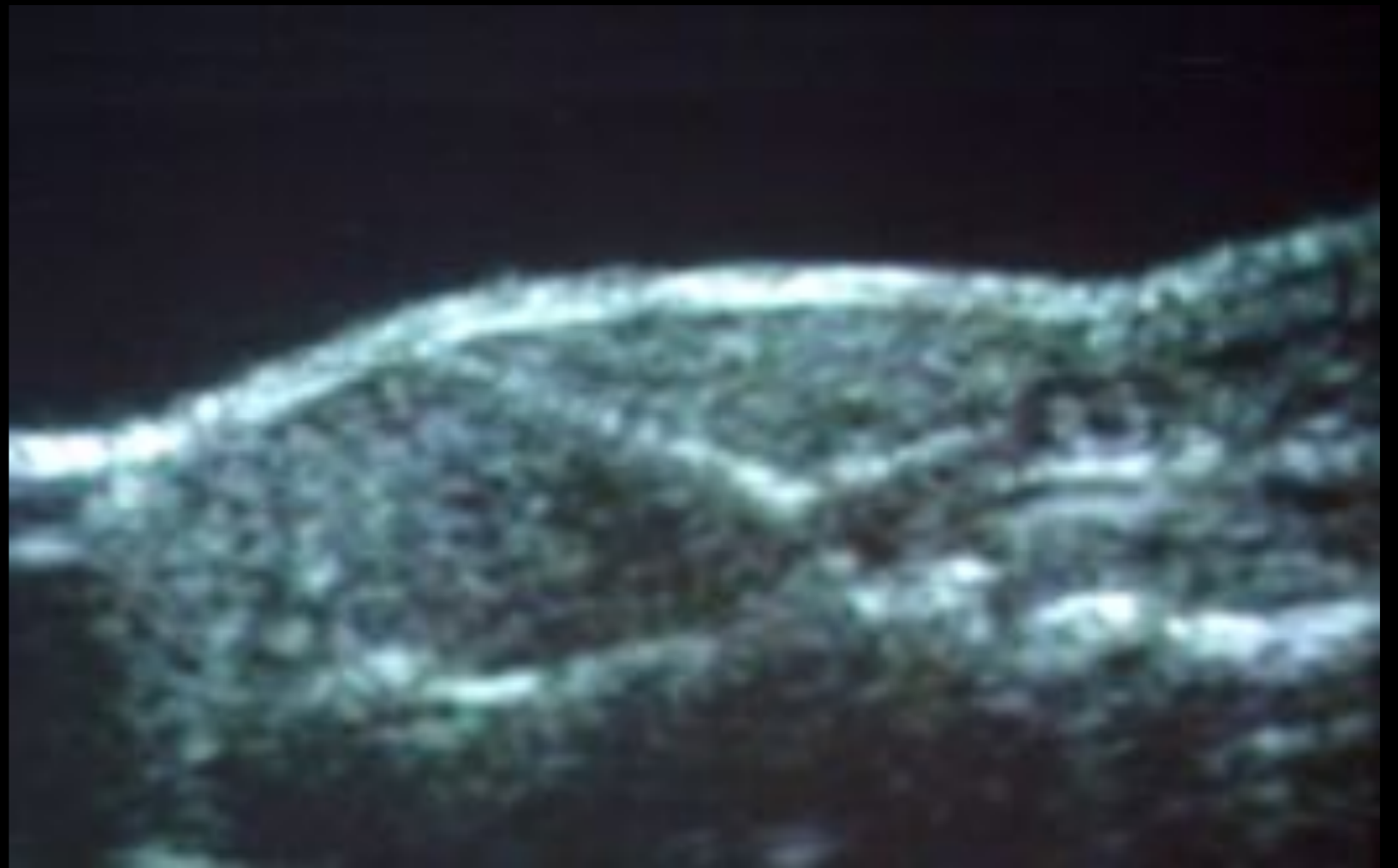
Foreign bodies

- Exam



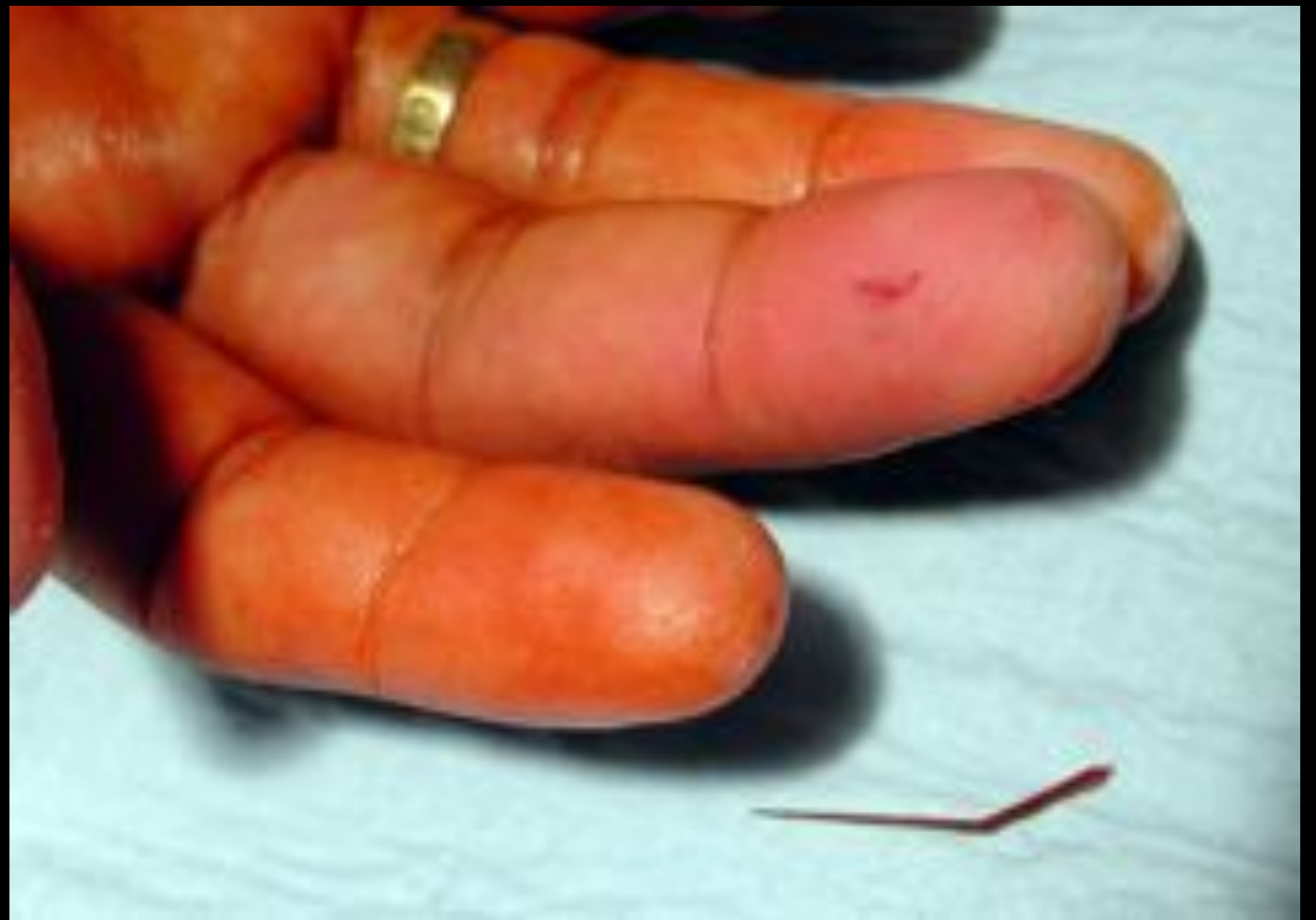Foreign bodies

- Ultrasound



Foreign bodies

- Post excision



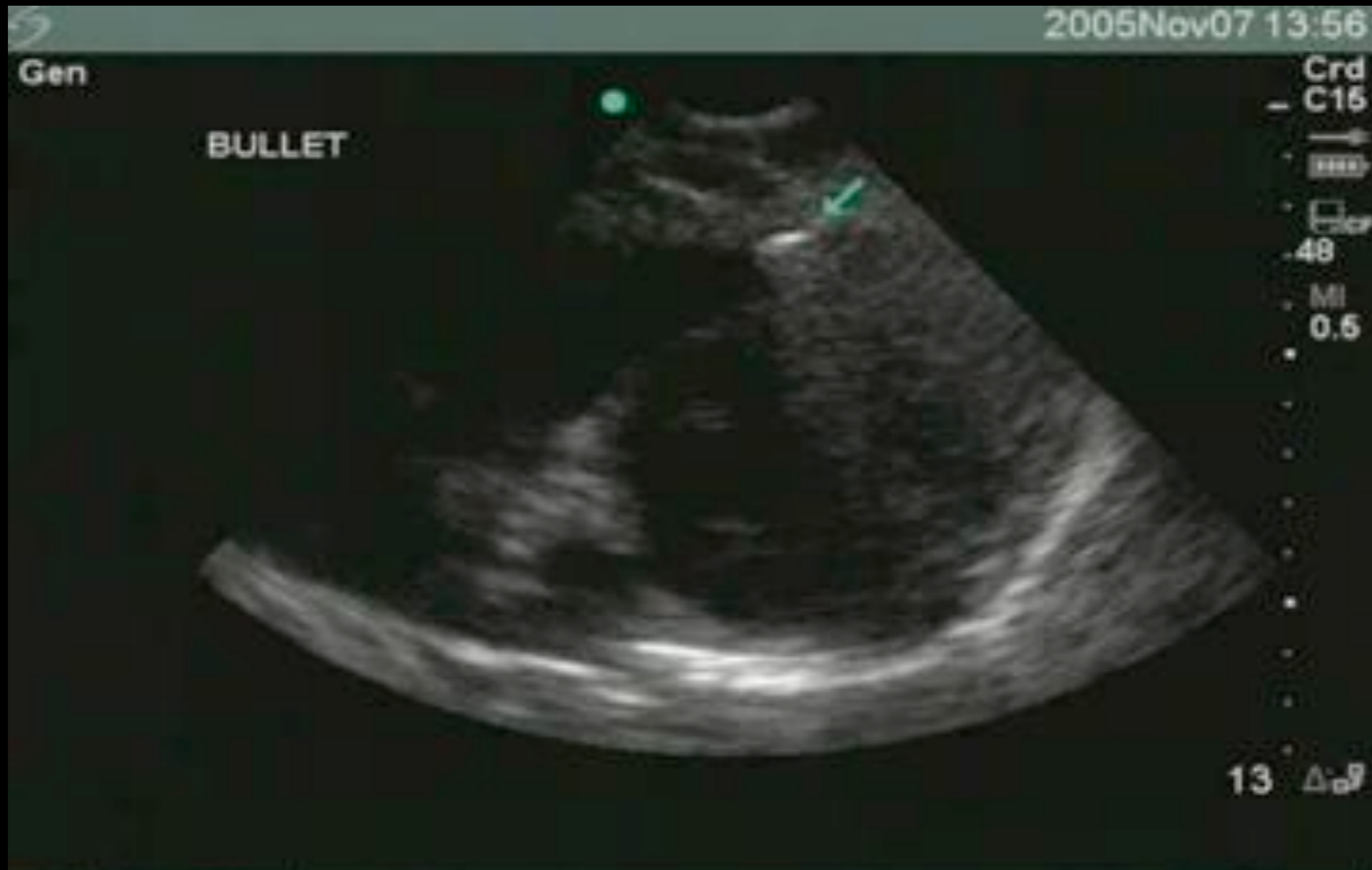Foreign bodies

- Why use ultrasound?
 - 40% FBs missed initially
 - Risk of infection
 - 2nd leading cause of litigation

Foreign bodies

- When to use ultrasound?
 - Xray normal & high suspicion
 - Unable to remove easily

Foreign bodies



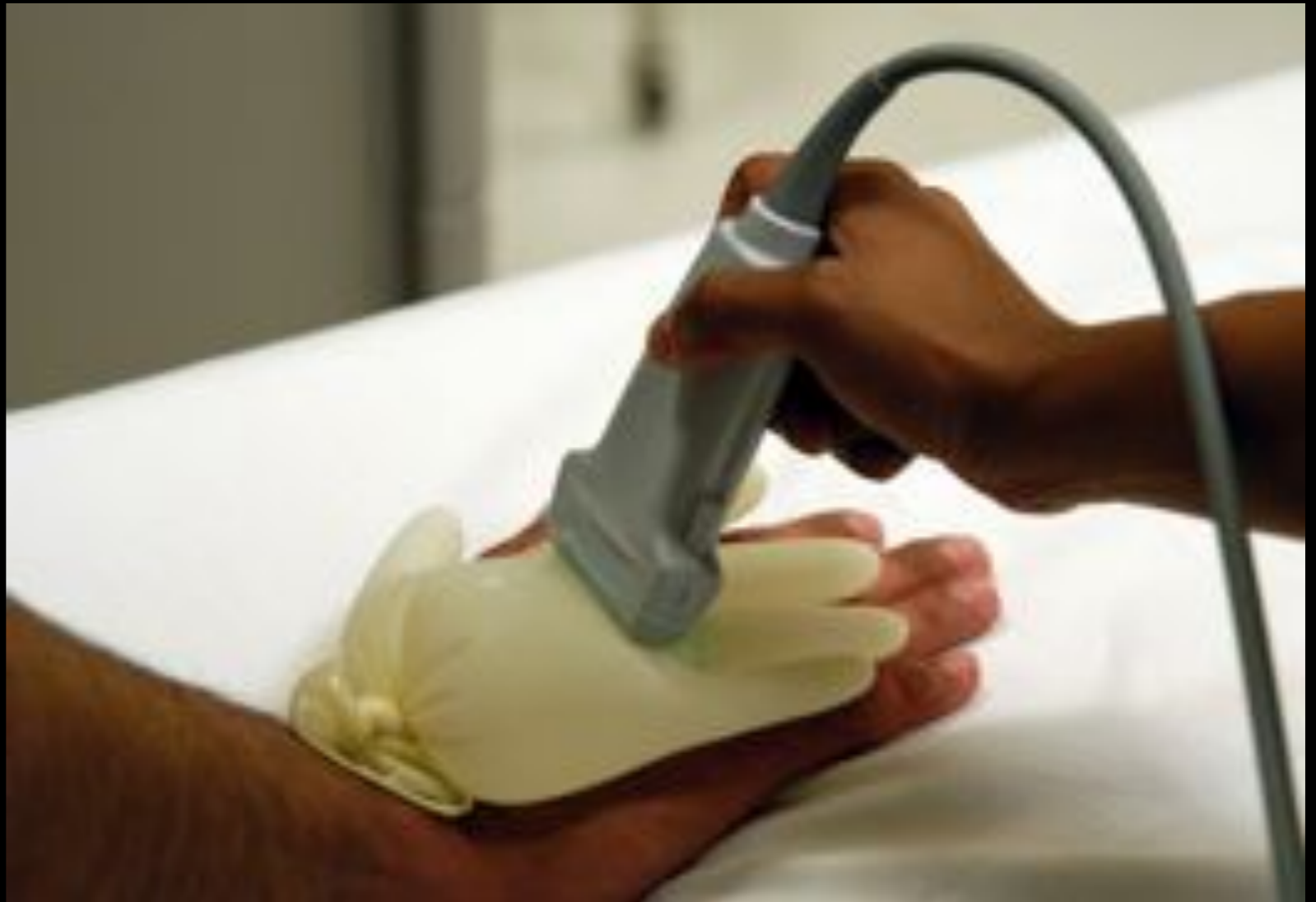Foreign bodies

- How to do ultrasound
 - Linear transducer
 - Shallow depth
 - 3D localization



Foreign bodies

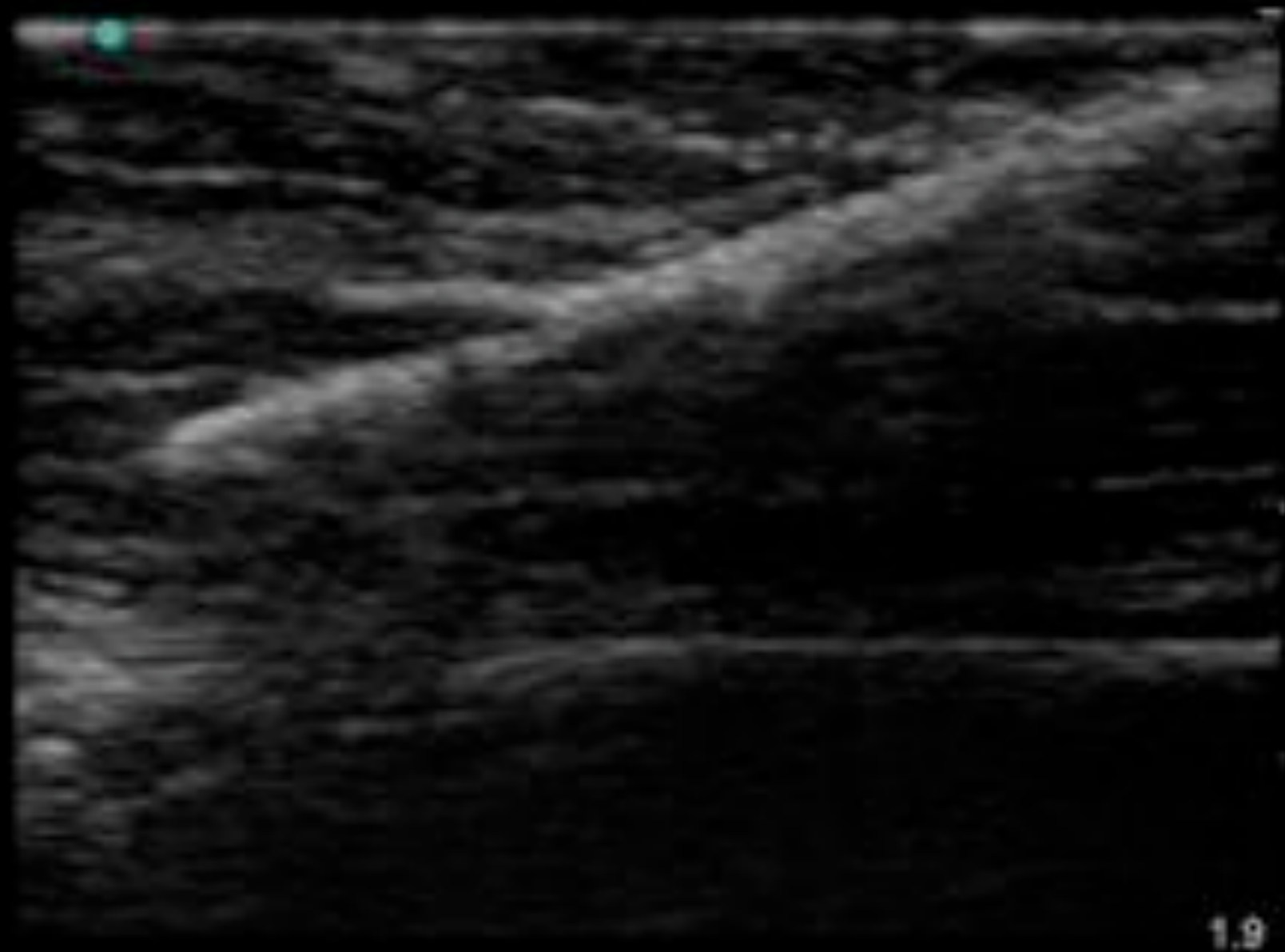
- How to do ultrasound



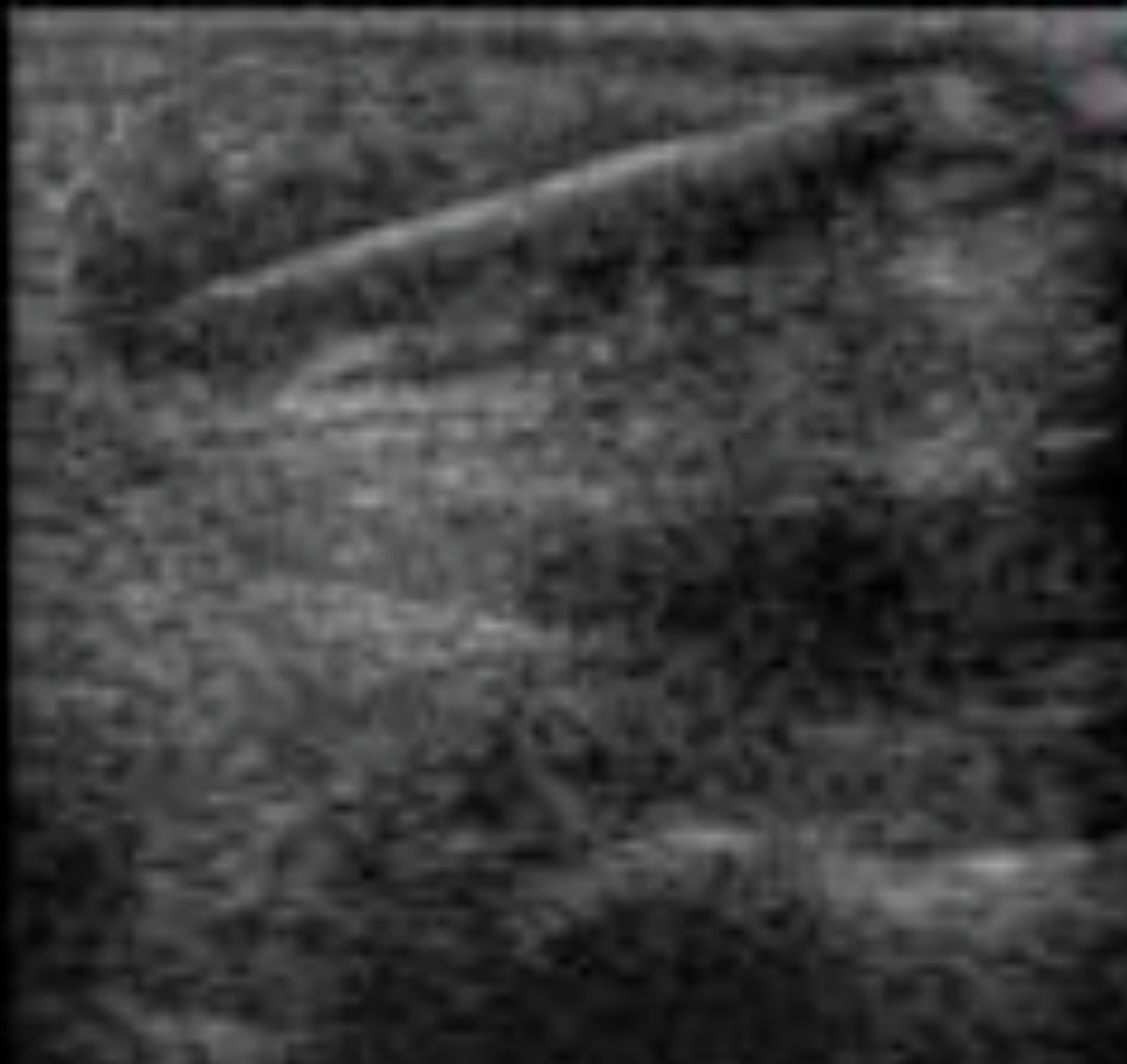Foreign bodies

- Ultrasound appearance

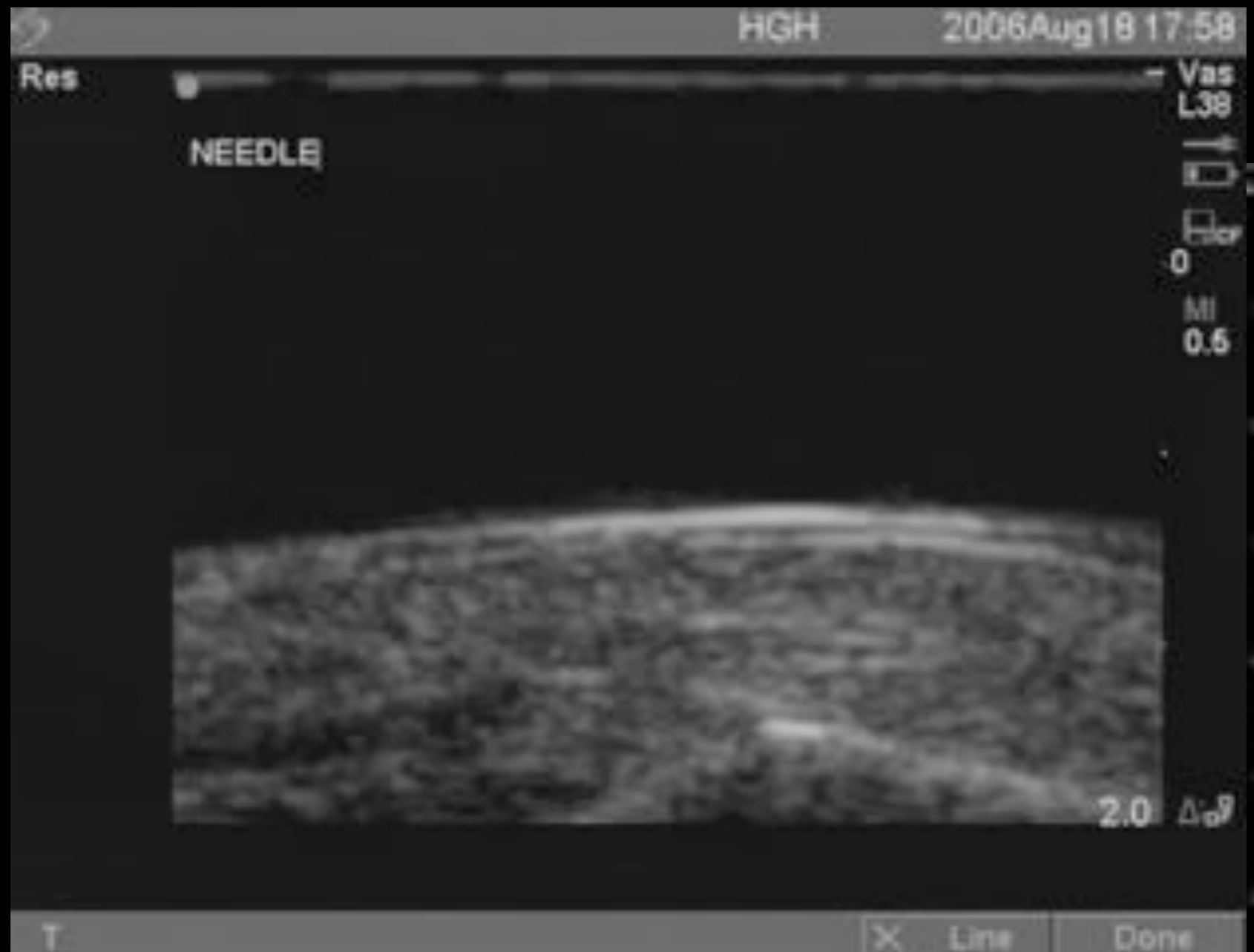
Foreign bodies



Foreign bodies

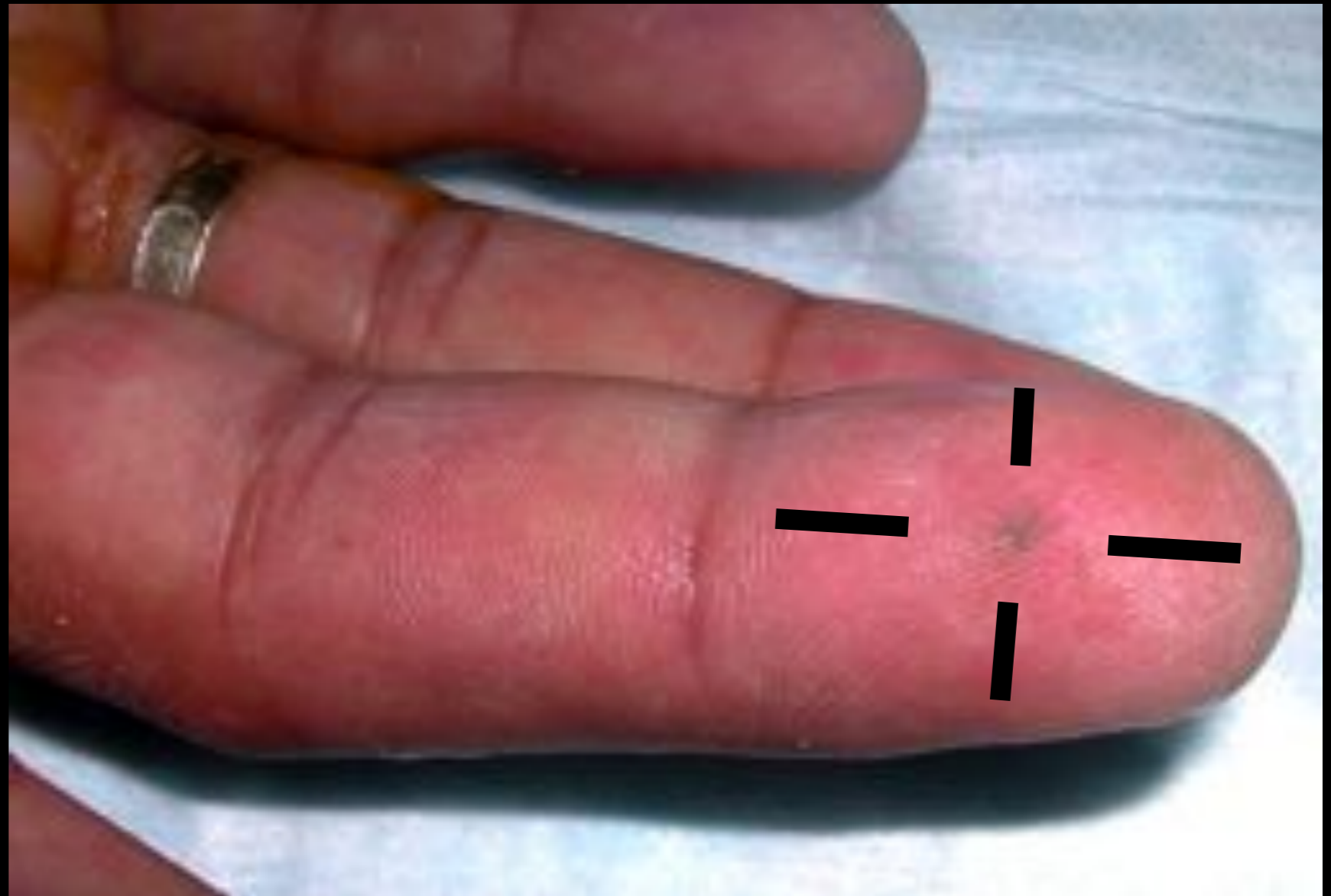

Foreign bodies



Foreign bodies

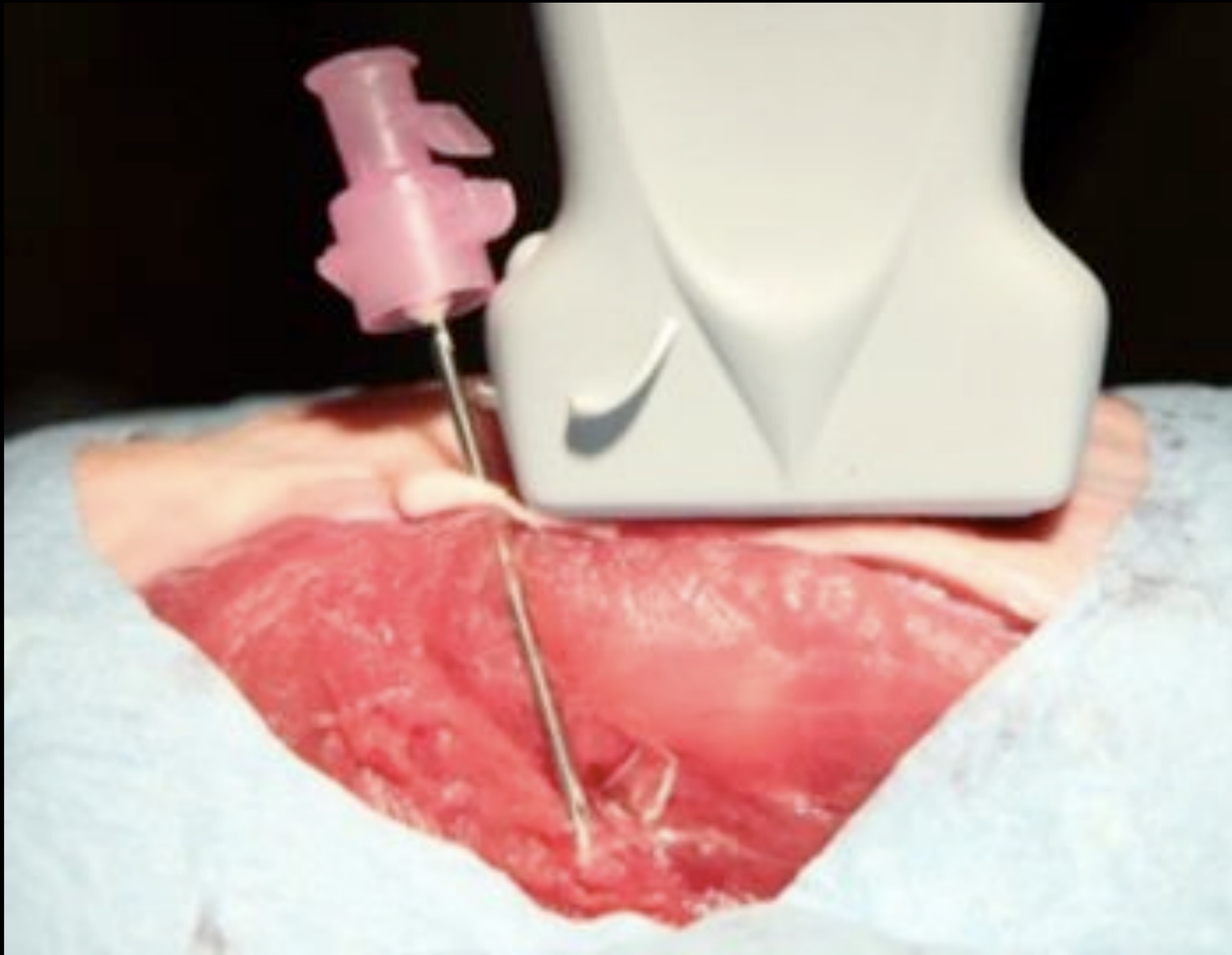
- Removal
- Marking location



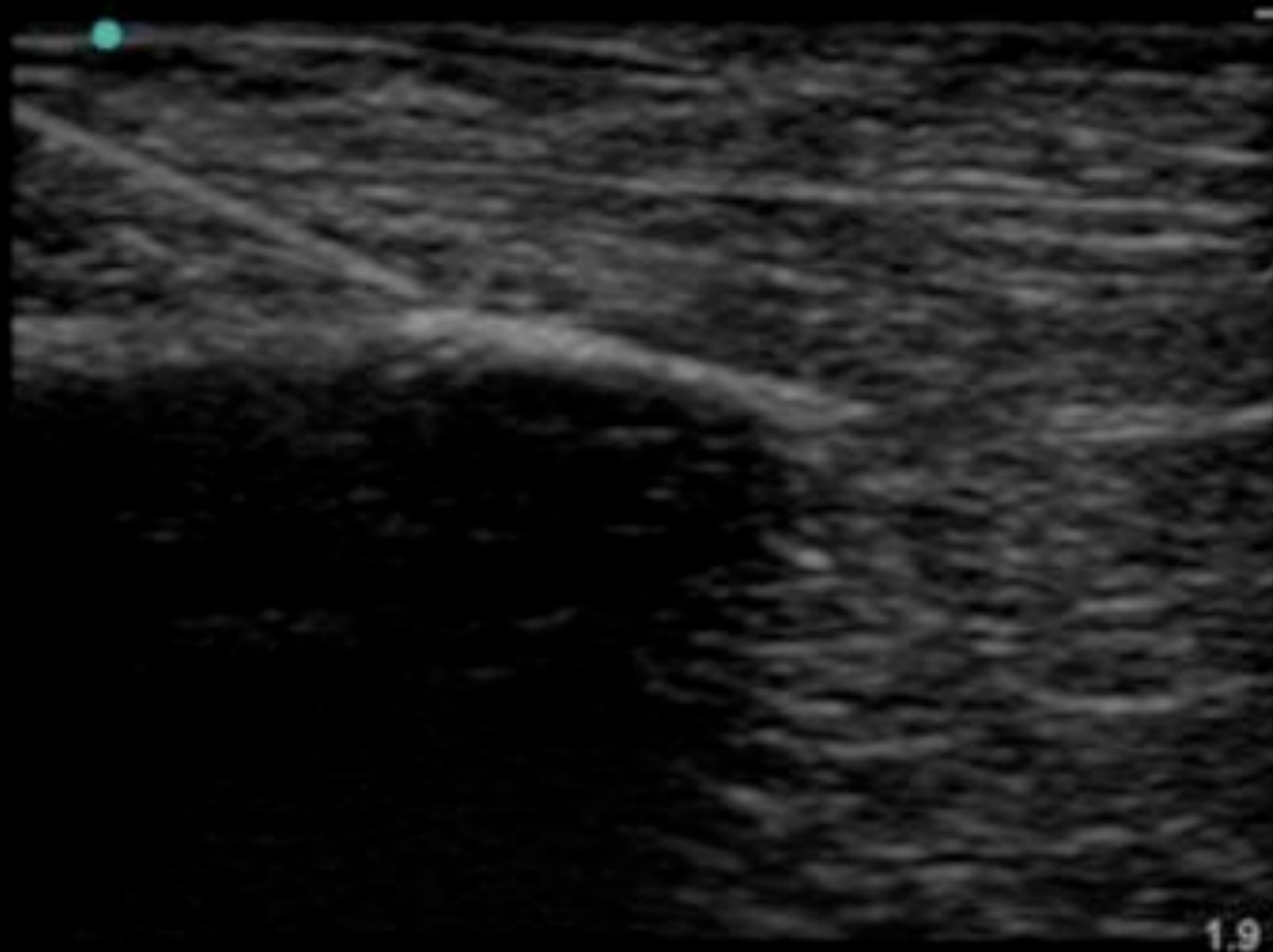
Foreign body

- Removal
 - I needle

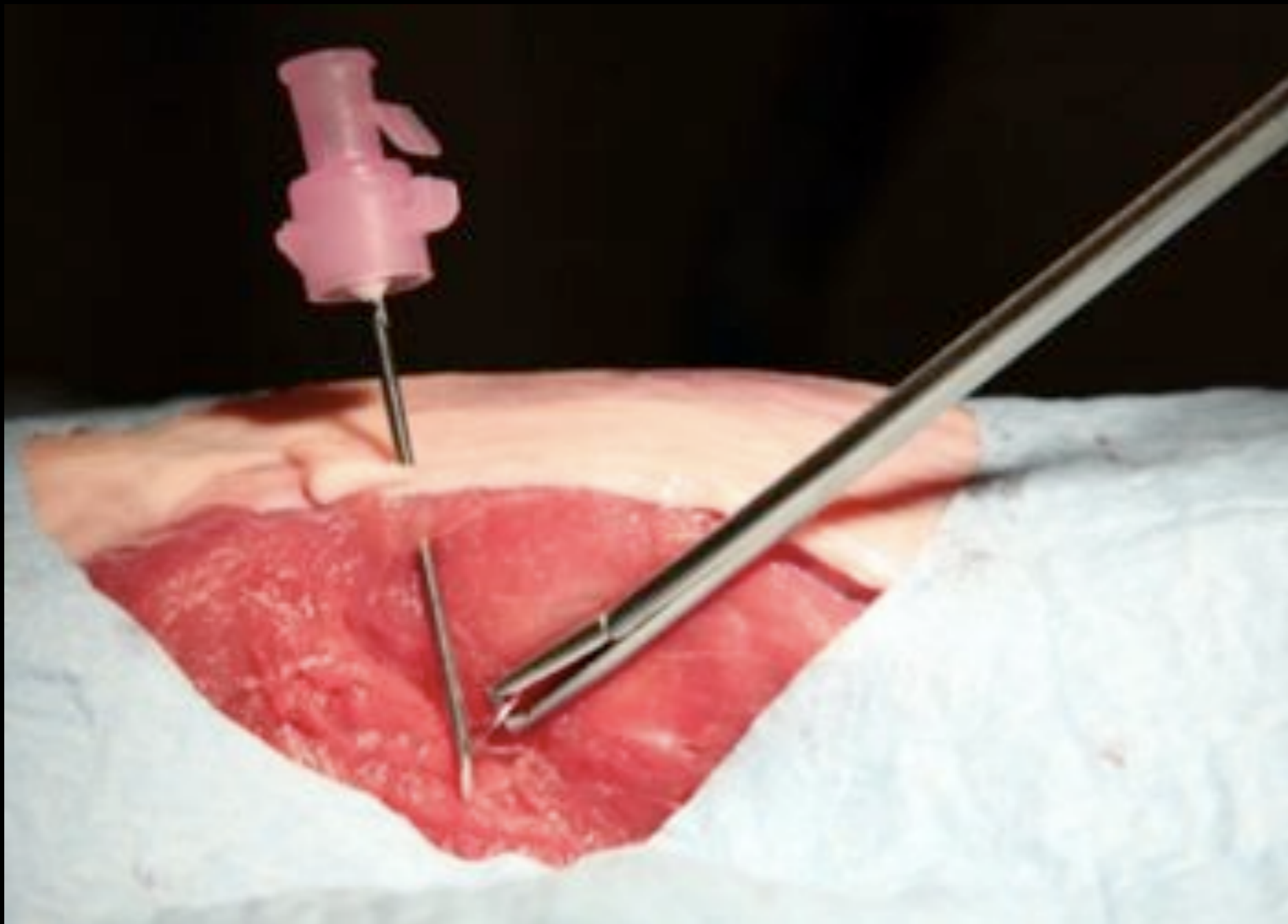
Foreign body



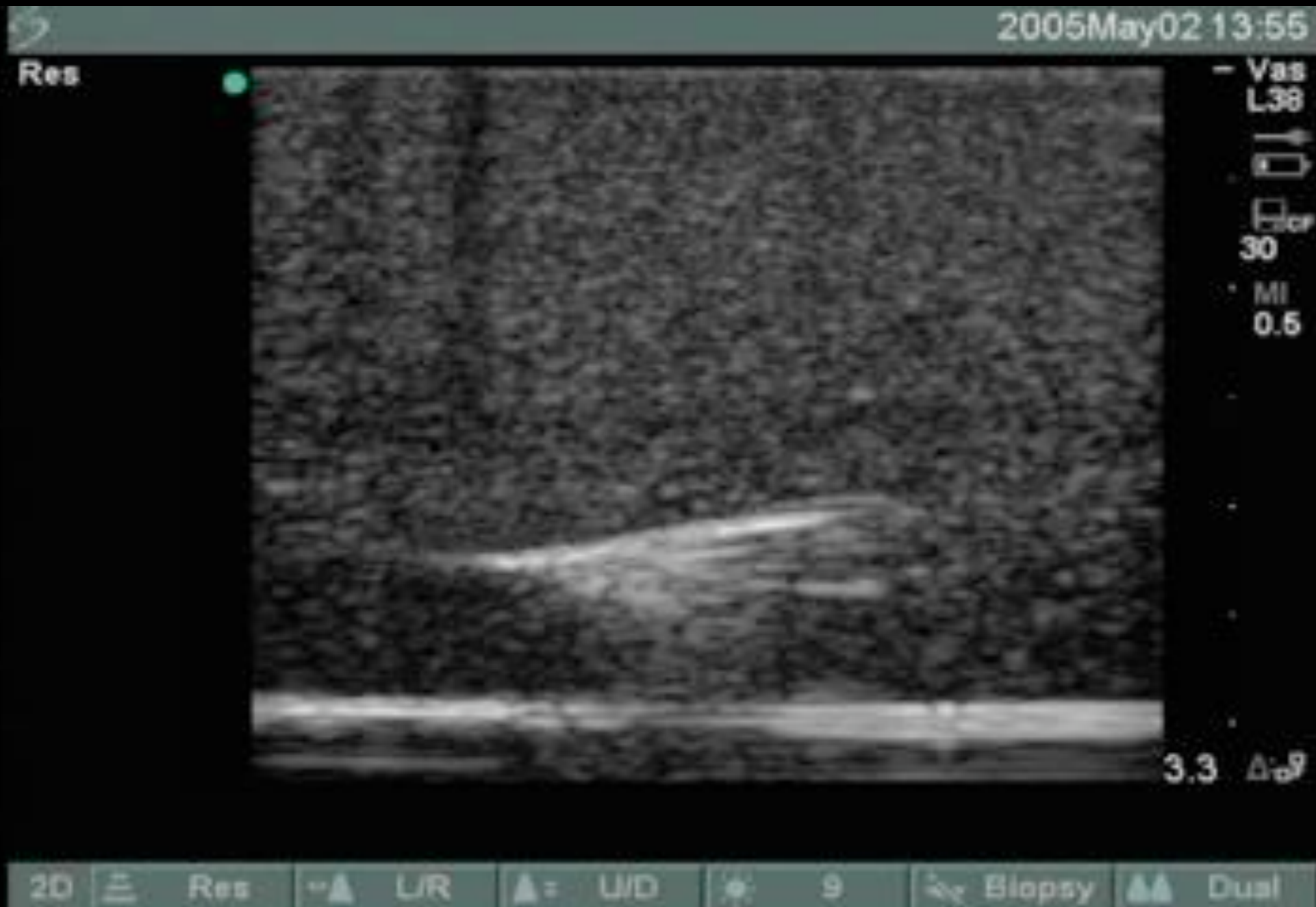Foreign body



Foreign body

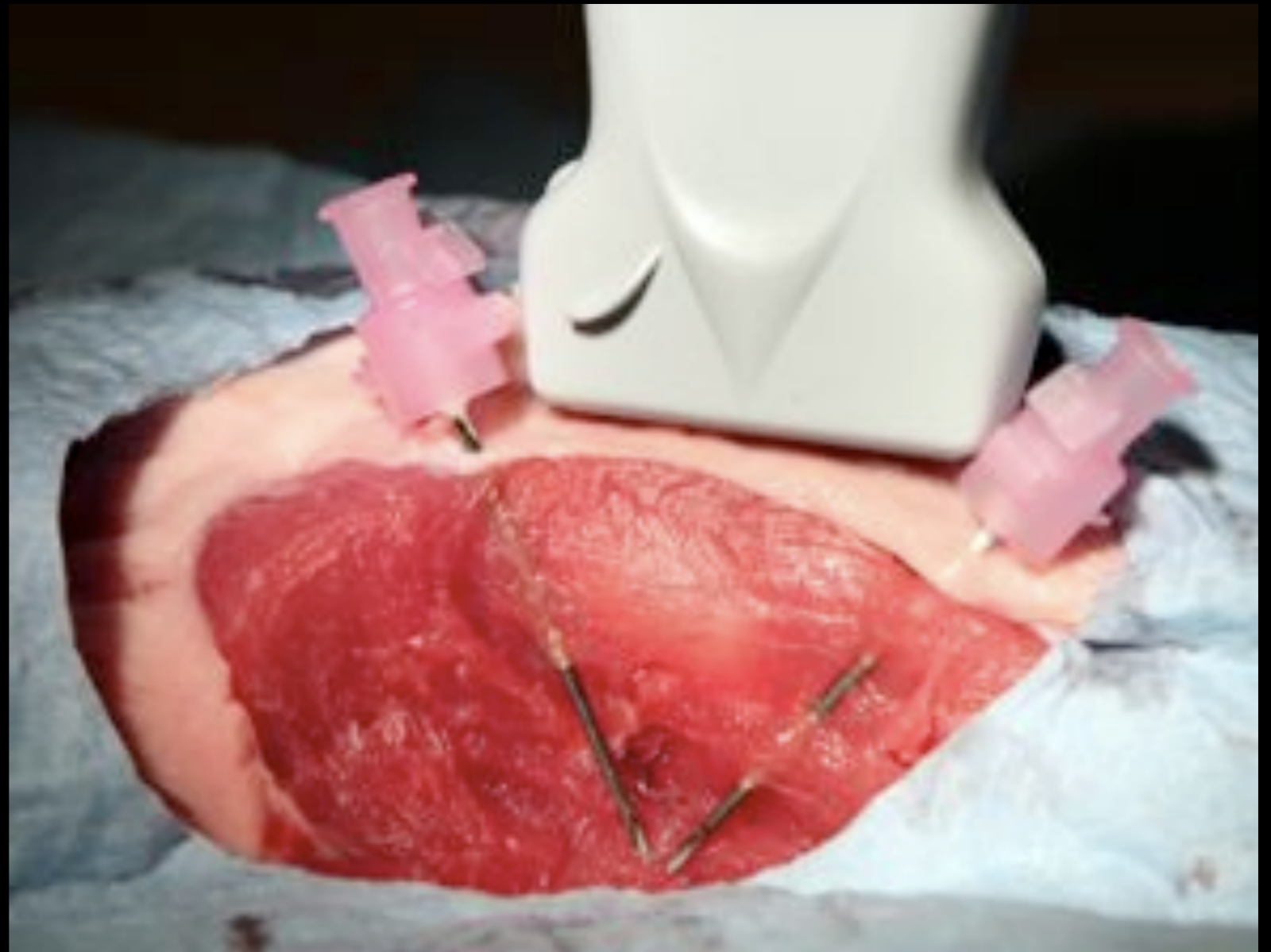


Foreign body



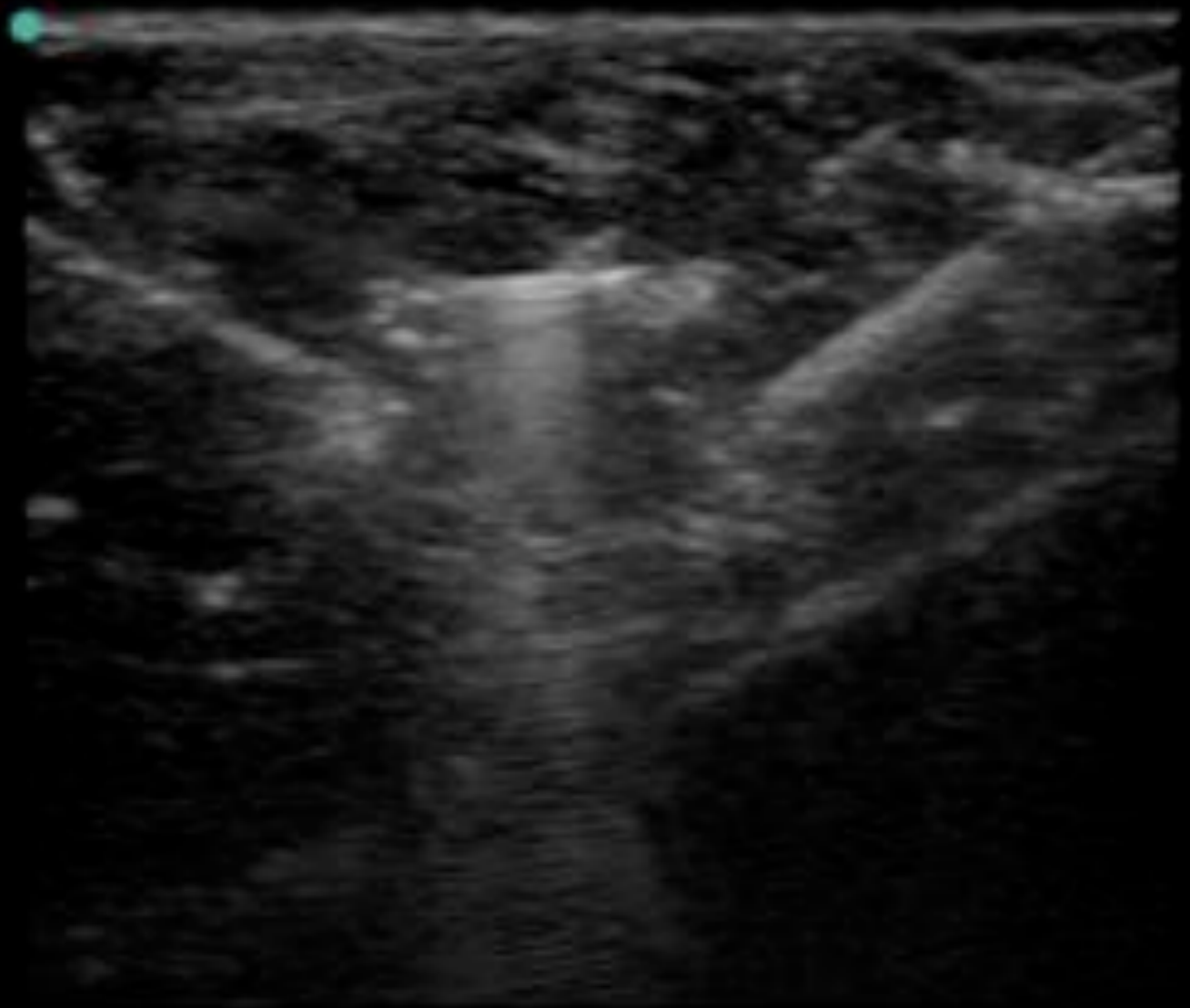Foreign bodies

- Removal
 - 2 needles



Foreign bodies

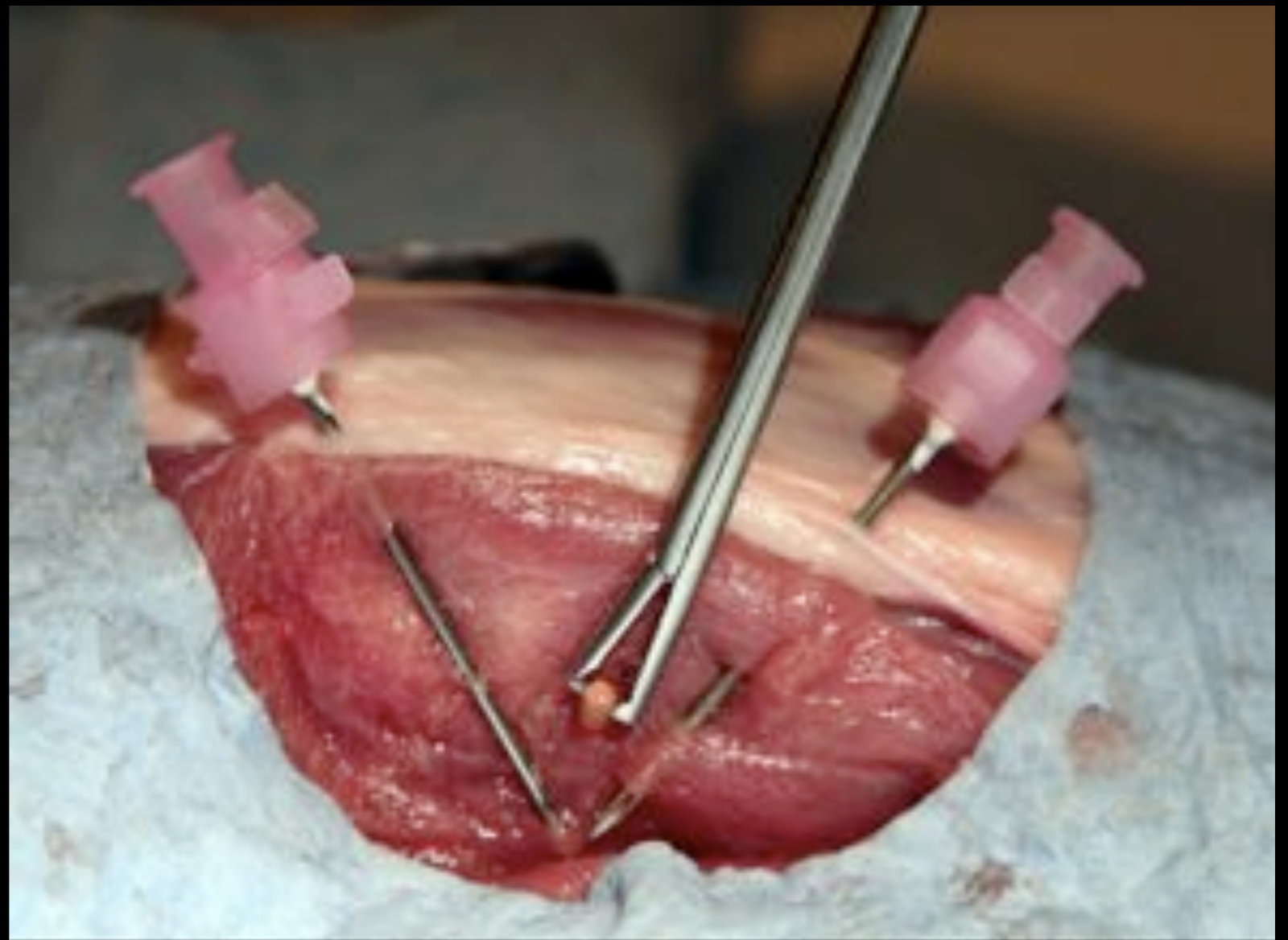
- Removal
 - 2 needles



2.2

Foreign bodies

- Removal
 - 2 needles



Foreign bodies

- Pitfalls
 - Bone
 - Too small
 - Fake-outs

Fin

- Obregado

