



## Emergency Ultrasound

The use of ultrasound at the bedside to answer focused clinical questions is a relatively recent development in the field of Emergency Medicine. This practice, known as Emergency Ultrasound, has many advantages both for the physician and the patient over traditional imaging modalities. It is safe, rapid and non-invasive and can be performed by a wide range of specialists including Radiologists and non-Radiologists. This rapid technique comes to the patient and therefore is ideal in the setting of acute illness or an unstable patient. It does not replace the accurate diagnostic report provided by formal radiological modalities such as CT scanning and departmental ultrasound.

Emergency ultrasound is used as an extension of the clinical examination to rule in or rule out key diagnosis in specific clinical settings. Examples of the clinical questions to be answered include:

1. Does this hypotensive patient have an abdominal aortic aneurysm?
2. In this trauma patient, is there free intra-peritoneal fluid?
3. In a patient in cardiac arrest is there pericardial tamponade or ventricular wall motion?

These are some basic questions that can be answered after a moderate amount of training in the appropriate setting. Further questions that can be asked are:

1. Does this patient with abdominal pain have gallstones?
2. Is there evidence of hydronephrosis in this patient with flank pain?
3. Does this patient have a subcutaneous foreign body?

Emergency bedside ultrasound can also be used to facilitate invasive procedures, this includes:

1. Placement of central venous catheters
2. The draining of pleural effusions and ascites
3. Localisation of subcutaneous foreign bodies.

The key question that any physician wishing to use emergency ultrasound should ask themselves is will a bedside ultrasound scan change or help the immediate management of the patient in the ED.

Bedside ultrasound can also be used to assess the haemodynamic status of a shocked patient; simple measures such as the amount by which the inferior vena cava collapses on inspiration (IVC collapse index), or an ultrasound estimation of the JVP in the patient who is able to sit at 45°, can provide an estimate of venous filling. And when combined with a comparison of the size of the right atria and ventricle to the left atria ventricle, this can provide an estimate of right sided pressure which can be useful when considering diagnosis such as pulmonary embolism.



# Emergency Ultrasound UK

## Background Information

Ultrasound technology allows the production of images by processing high frequency sound waves transmitted and received by an ultrasound probe. The frequencies used for medical ultrasound range from 2 – 15 megaHz, with lower frequencies used for abdominal and cardiac scanning and high frequencies used for superficial and detailed ultrasound. The modes of ultrasound used in emergency scanning include, B mode (or 2D ultrasound), M Mode used in cardiac ultrasound, and Doppler imaging when assessing flow. Some simple principles that help interpretation of ultrasound images are:

1. Different tissue types reflect or transmit ultrasonic waves in a variable manner leading to difference appearance in the ultrasound picture, i.e. bone or calcified structures such as gall stones are highly reflective and appear white. Fluid transmits ultrasonic waves and appears black. Soft tissue structures and organs reflect some sound and transmit the remainder, therefore, appearing grey. Air scatters sound waves and therefore is not visualised.
2. Air is the enemy. To prevent air distorting the picture, gel must be applied between the probe and the skin. Gentle pressure will also help to dislodge any air in the field.
3. Probe selection: A curved low frequency probe is used for abdominal scanning and often thoracic scanning. A high frequency linear ray probe is used for soft tissue scanning and vascular scanning. A phased ray probe is used for cardiac scanning.
4. High frequency settings provide a detailed picture but with less penetration, low frequency settings provide better penetration but with less detail.
5. Certain ultrasound properties which interfere with the picture generated, although they can distort the picture, can also be used to help with diagnosis. Examples include
  - (a) Acoustic shadowing behind calcified objects (useful to identify gall stones).
  - (b) Acoustic enhancement of fluid filled spaces (used as acoustic windows into the body)
  - (c) Mirror artefact
  - (d) Reverberation Artefact
6. Structures should be viewed in at least 2 plains, traditionally longitude and transverse. It is important to orientate the probe directly to the patient, especially when learning this skill.



## **Level 1 Applications**

### **Focused Assessment by Sonography in Trauma (FAST)**

The objective of the FAST scan is the detection of free intra-peritoneal fluid or pericardial fluid in the trauma patient. It is a highly sensitive test for answering this binary question. The scan involves 4 views: the right upper quadrant (hepatorenal angle / Morrison's Pouch); the left upper quadrant (spleno renal angle); the pelvic view; and the subxiphoid/pericardial view. The limitations of this study need to be understood, yet when used appropriately, it is highly useful tool in the trauma room.

### **Focused Aortic Scanning**

Emergency bedside scanning of the aorta again asks a binary question: Is there an abdominal aortic aneurysm (AAA)? The scan does not determine whether this aneurysm is leaking, rather just that it is present. In the hands of appropriately trained Emergency Physicians or Surgeons, ultrasound is both highly specific and sensitive. The views involve longitude and transverse sections of the aorta from diaphragm to bifurcation. The overwhelming benefit of this test is the detection of unsuspected AAA in the shocked patient.

### **Focused Cardiac Scanning**

Bedside cardiac ultrasound evaluation in the ED is limited to a global assessment of contractility and the detection of pericardial effusions/tamponade. This is applied to patients who are in an arrest or shocked condition. The utility of this scan is to highlight the need for intervention such as pericardiocentesis, and also to help with decisions such as the appropriateness of ongoing resuscitation attempts.

### **Detection of Pleural Fluid**

Bedside ultrasound can be used to differentiate pleural effusions from consolidation, which may not be apparent on a plain chest radiograph. It can also be useful for marking a safe entry point for aspiration. Ultrasound is also useful in the detection of pneumothorax where the absence of a gliding sign and comet tail appearance indicates lack of contact between the visual and parietal pleura. M Mode ultrasonography also shows a typical pattern which varies in patients with pneumothorax, this is known as the 'seashore appearance.'

### **Procedural Ultrasound**

There is mounting evidence that ultrasound can improve the safety and accuracy of interventional procedures such placement of central venous catheters and aspiration of fluid collections such as pleural effusions and ascites. The linear probe is used to identify anatomical structures and to guide these interventional procedures. It is important to emphasise the need for the normal aseptic precautions to be taken in this setting.

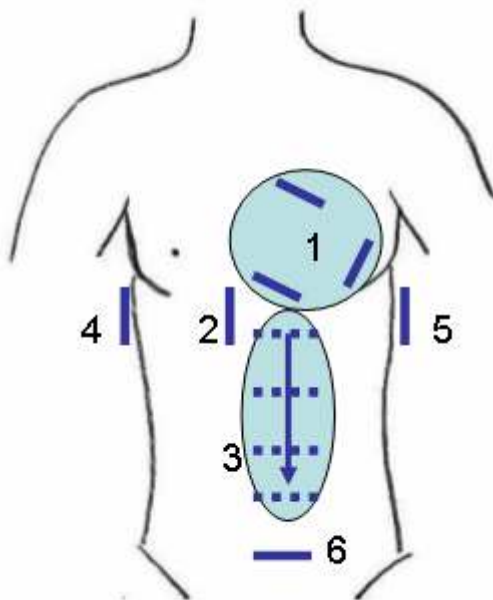
## **Level 2 and Other Screening Applications**

Although not widely used in all Emergency Departments, some Emergency Physicians use bedside ultrasound to screen for conditions such as gallstones, cholecystitis, hydronephrosis, and also the identification of a definite intrauterine pregnancy in the evaluation of patients with possible ectopic pregnancy.

## Shock Ultrasound (ACES)

Abdominal and Cardiac Evaluation by Sonography in Shock (ACES) is a combination of individual applications in the undifferentiated hypotensive patient which can provide a useful pointer to possible underlying aetiologies. A common combination includes focused scans of the aorta, FAST (for free intraperitoneal fluid, pericardial tamponade and general cardiac wall motion) and an IVC collapse index. Again, this type of screen is an extension of the clinical examination and does not provide a formal report.

**Figure 1. The 6 views of the ACES scan (Cardiac, IVC, Aorta, Right upper quadrant, Left upper quadrant, and pelvis)**



## Training in Emergency Ultrasound and Record Keeping

Local and national guidelines are available which describe the requirements for training in emergency ultrasound. The principle of competency based assessment rather than assessment based purely on numbers of scans performed should be followed. A clear record of findings should always be made in the notes as well as a copy of scans for further review.