


The ACES scan

Ultrasound in hypotension

Richard Kendall
Paul Atkinson


emergencyultrasound.org.uk



The ACES scan

- **A**bdominal (and)
- **C**ardiac
- **E**valuation (with sonography in)
- **S**hock


emergencyultrasound.org.uk



The ACES scan

- Extension of more established emergency medicine uses of ultrasound
- Abdominal component
- Cardiac component
- (Peripheral component)


emergencyultrasound.org.uk



Case 1


- 'Red call'
- Elderly female – collapsed and absent radial pulse
- Arrives – peri-arrest
- Groaning
- Initial resuscitation
- ACES scan

emergencyultrasound.org.uk




Case 1

- Huge AAA, tender
- Terminal care instituted



emergencyultrasound.org.uk



Case 2

- 'Red call'
- 62 year old man
- Hypotension, epigastric pain
- Unwell ?AAA
- 10 minutes

emergencyultrasound.org.uk

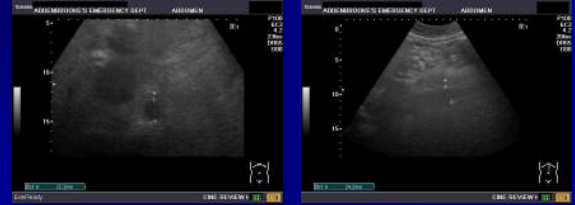
Case 2

- BP 74/54, Pulse 110, clammy
- Initial resuscitation underway
- ACES scan

emergencyultrasound.org.uk

Abdomen

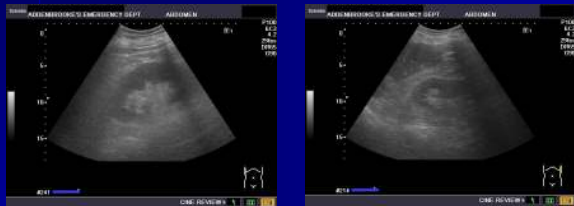- No AAA



emergencyultrasound.org.uk

Abdomen

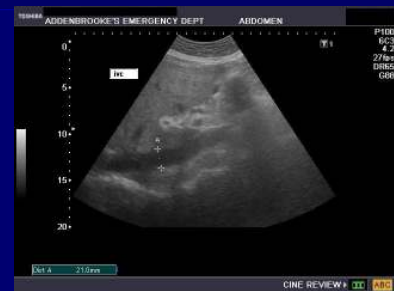- No free fluid



emergencyultrasound.org.uk

Abdomen - IVC

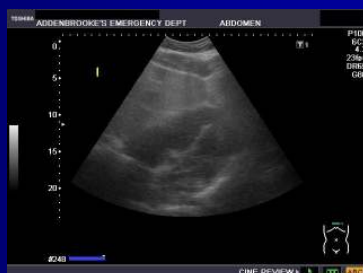- Slight collapse on inspiration



emergencyultrasound.org.uk

Cardiac - subcostal

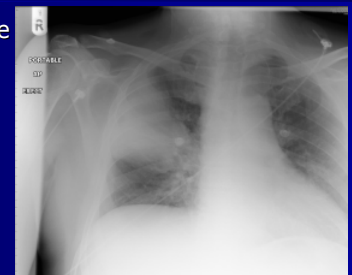
- No pericardial effusion
- Hyperdynamic
- Not small
- RV not dilated



emergencyultrasound.org.uk

CXR

- Fluid challenge
- IV antibiotics
- IJ line (us control)
- ICU



emergencyultrasound.org.uk

ACES scan



- Aim is to help identify the likely cause of hypotension

emergencyultrasound.org.uk

Causes of Hypotension



- Hypovolaemia
- Obstructive (tamponade)
- Obstructive (PE)
- Cardiogenic
- Distributive (septic)

emergencyultrasound.org.uk

Hypovolaemia



Two aims of ACES scan:-

- To establish existence of hypovolaemic state
 - IVC
 - 'collapse index'
 - Cardiac
 - Small chamber size 'small heart'
 - Aggressive wall motion 'hyperdynamic'
- To identify possible causes
 - AAA
 - Free fluid (haemoperitoneum)

emergencyultrasound.org.uk

Tamponade



Aims of ACES scan to:-

- Identify pericardial effusion
- Collapse RA/RV during diastole = tamponade

emergencyultrasound.org.uk

PE



ACES scan aims to identify:-

- RV dilatation
 - RV hypokinesis
 - Paradoxical septal motion
- IVC distension
- (Peripheral views for DVT)

emergencyultrasound.org.uk

Cardiogenic



ACES scan aims to identify gross abnormalities of cardiac:-

- Size
 - Normal
 - Small
 - Dilated
- Motion
 - Normal
 - Hyperdynamic
 - Hypodynamic

Hypodynamic myocardium = cardiogenic

emergencyultrasound.org.uk

Sepsis



ACES scan aims to identify:-

- Hyperdynamic left ventricular function
- Hyperdynamic heart has sensitivity of 33% and a specificity of 94% for sepsis

Diagnostic accuracy of left ventricular function for identifying sepsis among emergency department patients with non-traumatic symptomatic undifferentiated hypotension
Jones A et al
Shock 2005 Dec;24(6) :513-7

emergencyultrasound.org.uk

ACES scan - 6 windows



1. Cardiac
2. IVC
3. Aorta
4. RUQ
5. LUQ
6. Pelvis

emergencyultrasound.org.uk

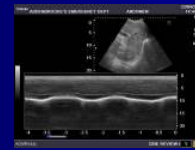
IVC and collapse index



- Relationship between IVC pressure and RA pressure
- Identify IVC
- Measure in inspiration and expiration
- M mode
- Calculate 'collapse index'

emergencyultrasound.org.uk

IVC and collapse index



emergencyultrasound.org.uk

Collapse Index



- Inspiration – IVC collapses slightly
- Expiration – IVC maximal diameter

emergencyultrasound.org.uk

Collapse Index (CI)



$$CI = \frac{\text{Max diameter} - \text{Min diameter}}{\text{Max diameter}} \times 100\%$$

Maximum diameter - expiration
Minimum diameter - inspiration

emergencyultrasound.org.uk



Collapse Index

- CI > 50% = RA pressure < 10mmHg
- CI < 50% = RA pressure > 10mmHg

Noninvasive estimation of right atrial pressure from the inspiratory collapse of the inferior vena cava

Kircher BJ et al

Am J Cardiol 1990 Aug 15;66(4):493-6

emergencyultrasound.org.uk



ACES scan - subcostal

- Pericardial effusion
- Gross assessment of cardiac wall motion
 - Normal
 - Hypodynamic
 - Hyperdynamic
- Gross assessment of cardiac chamber size

emergencyultrasound.org.uk



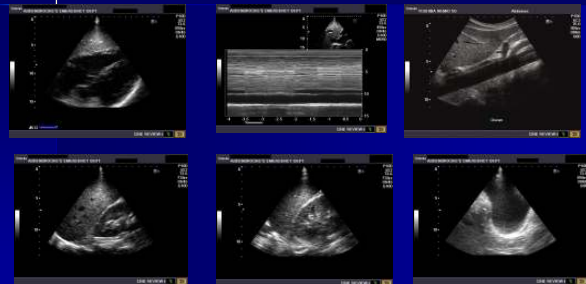
ACES scan – additional views

- Thoracic views – parasternal, apical
- Augment subcostal view
- (Peripheral views – DVT)

emergencyultrasound.org.uk



Summary ACES scan



emergencyultrasound.org.uk